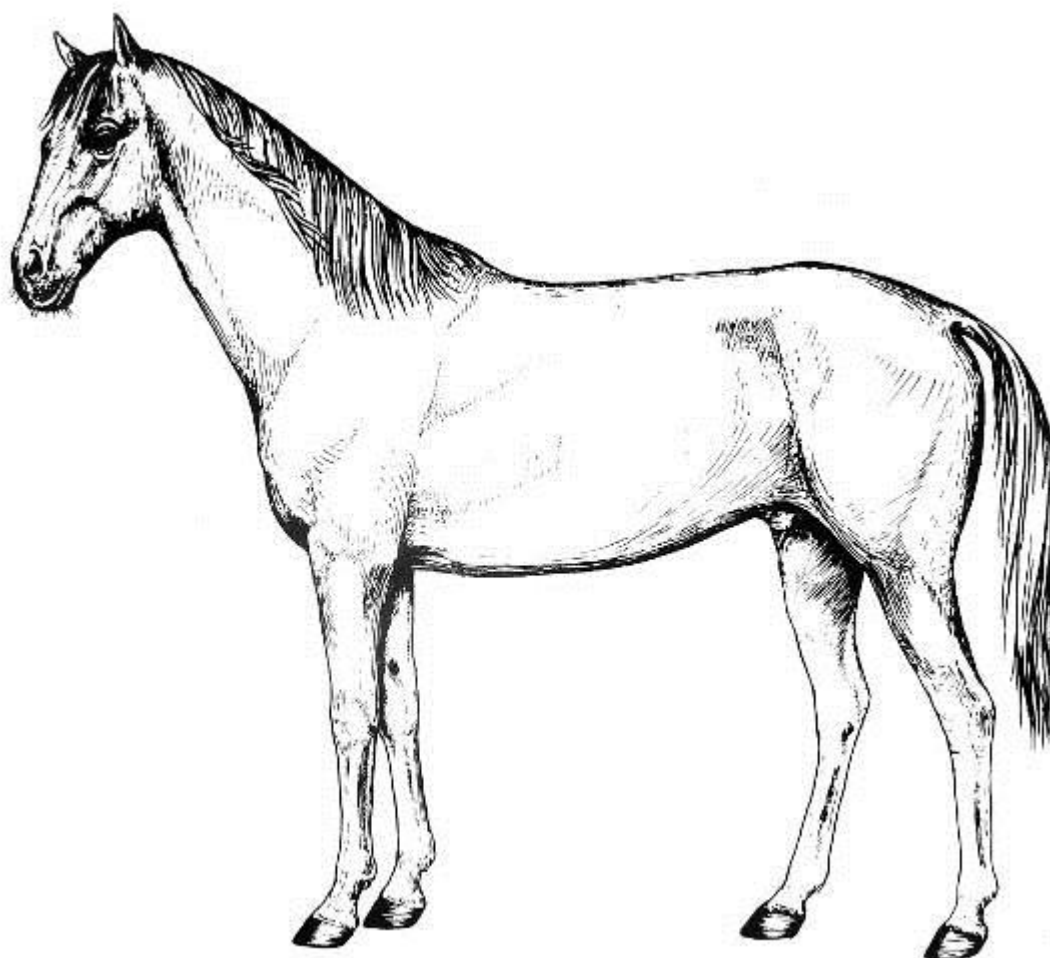


UNIC - UNIVERSIDADE DE CUIABÁ
FACULDADE DE MEDICINA VETERINÁRIA
DISCIPLINA DE CIÊNCIAS MORFOFUNCIONAIS
APLICADAS A MEDICINA VETERINÁRIA I

Roteiro de aula prática de Anatomia Veterinária

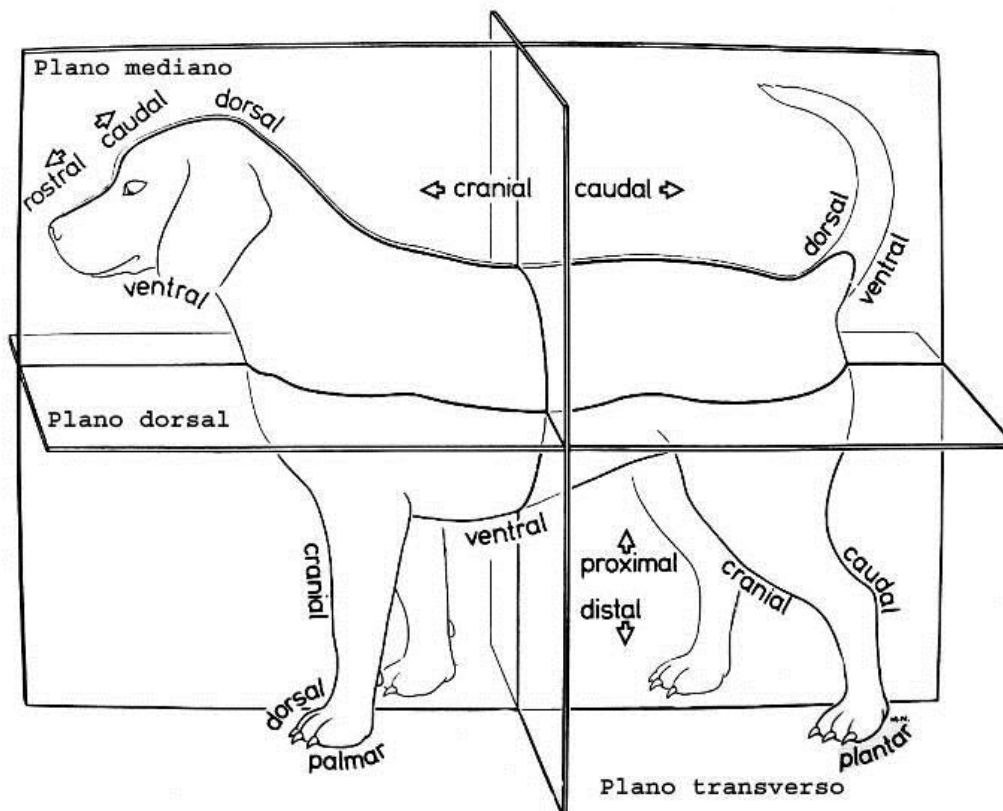


Profa. Juliana Normando Pinheiro

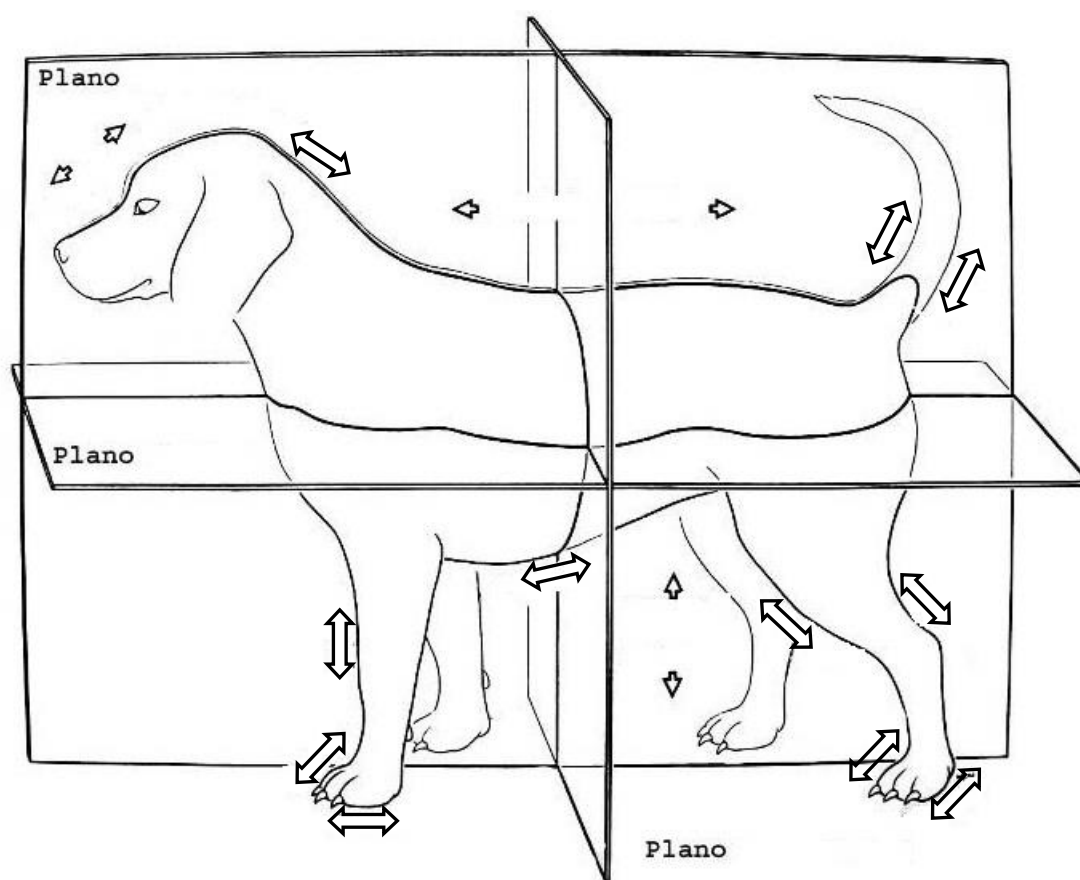
SUMÁRIO

Termos de posição e planos de secção do corpo dos animais domésticos	p. 03
Aparelho locomotor - Osteologia.....	p. 05
Aparelho locomotor - Artrologia.....	p. 44
Aparelho locomotor - Miologia.....	p. 58

Termos de posição e planos de secção do corpo dos animais domésticos

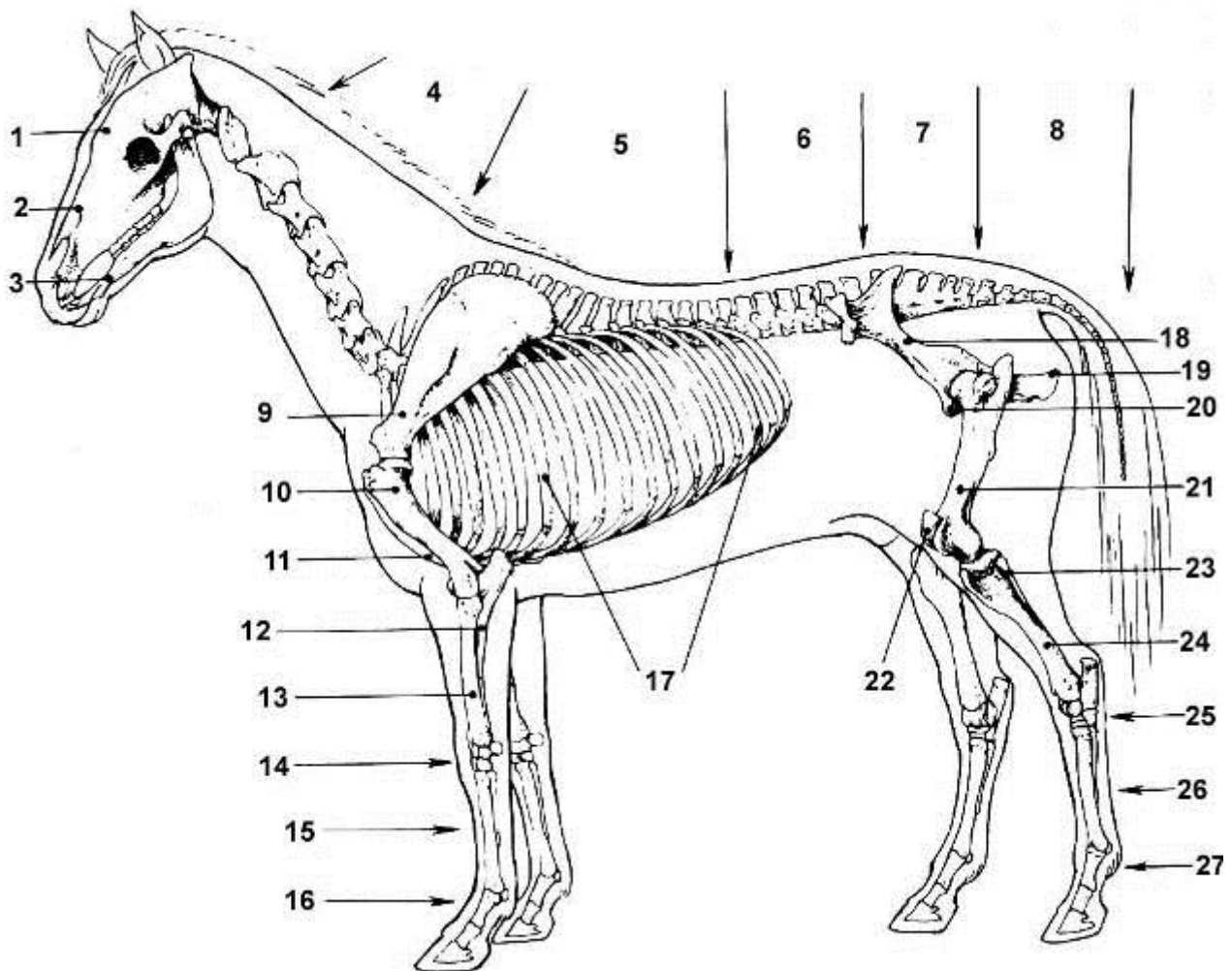


Pinte e denomine os Planos de Construção a seguir e Assinale os termos de posição indicados na figura pelas setas



APARELHO LOCOMOTOR OSTEOLOGIA

ESQUELETO DO EQUINO

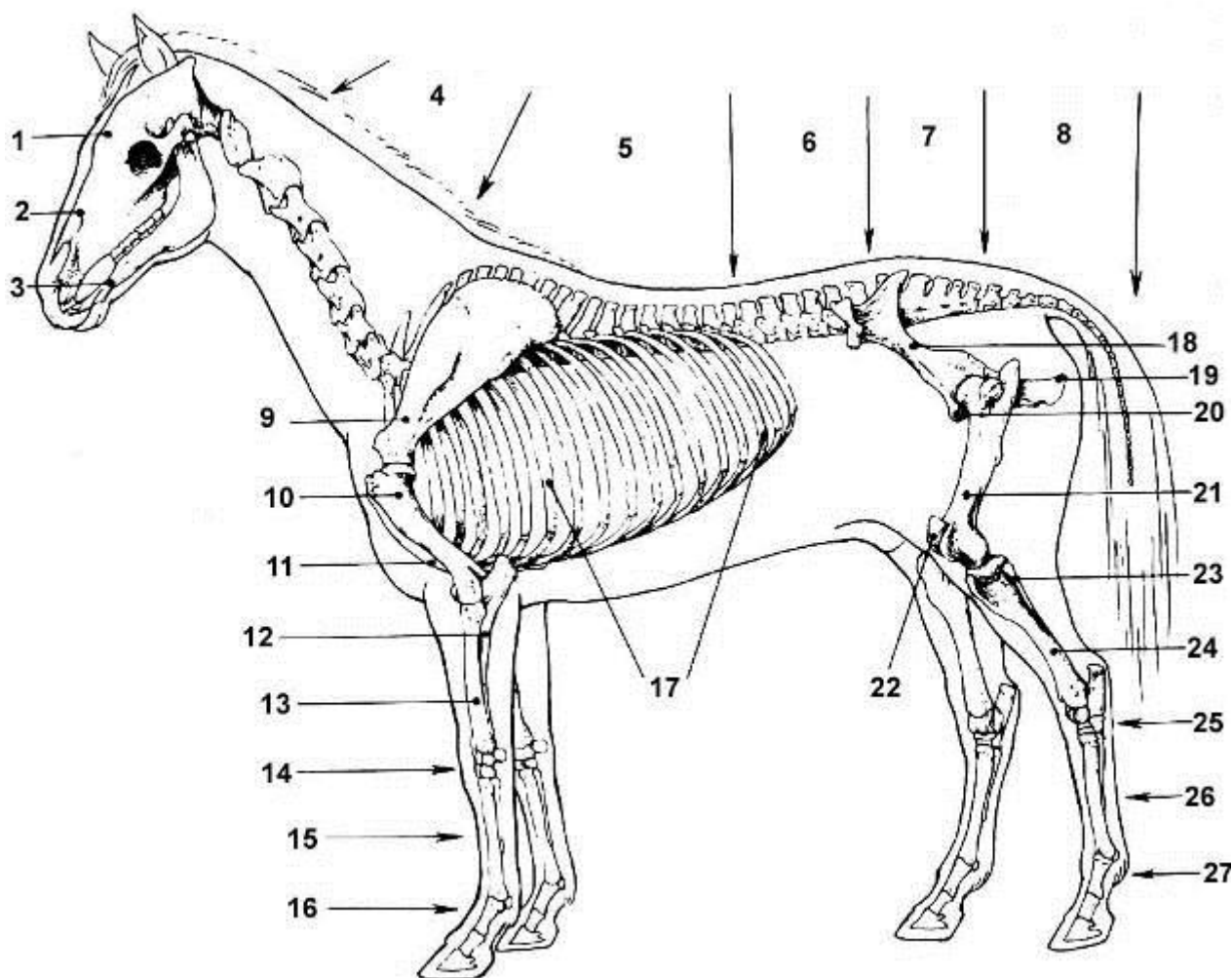


vista lateral

- 1 - crânio
- 2 - face
- 3 - mandíbula
- 4 - vértebras cervicais
- 5 - vértebras torácicas
- 6 - vértebras lombares
- 7 - vértebras sacrais (osso sacro)
- 8 - vértebras caudais
- 9 - escápula
- 10 - úmero
- 11 - esterno
- 12 - ulna
- 13 - rádio
- 14 - ossos do carpo
- 15 - ossos do metacarpo
- 16 - falanges (proximal, média, distal)

- 17 - costelas
- 18 - ílio
- 19 - ísquio
- 20 - púbis
- 21 - fêmur
- 22 - patela
- 23 - fíbula
- 24 - tíbia
- 25 - ossos do tarso
- 26 - ossos do metatarso
- 27 - falanges (proximal, média, distal)

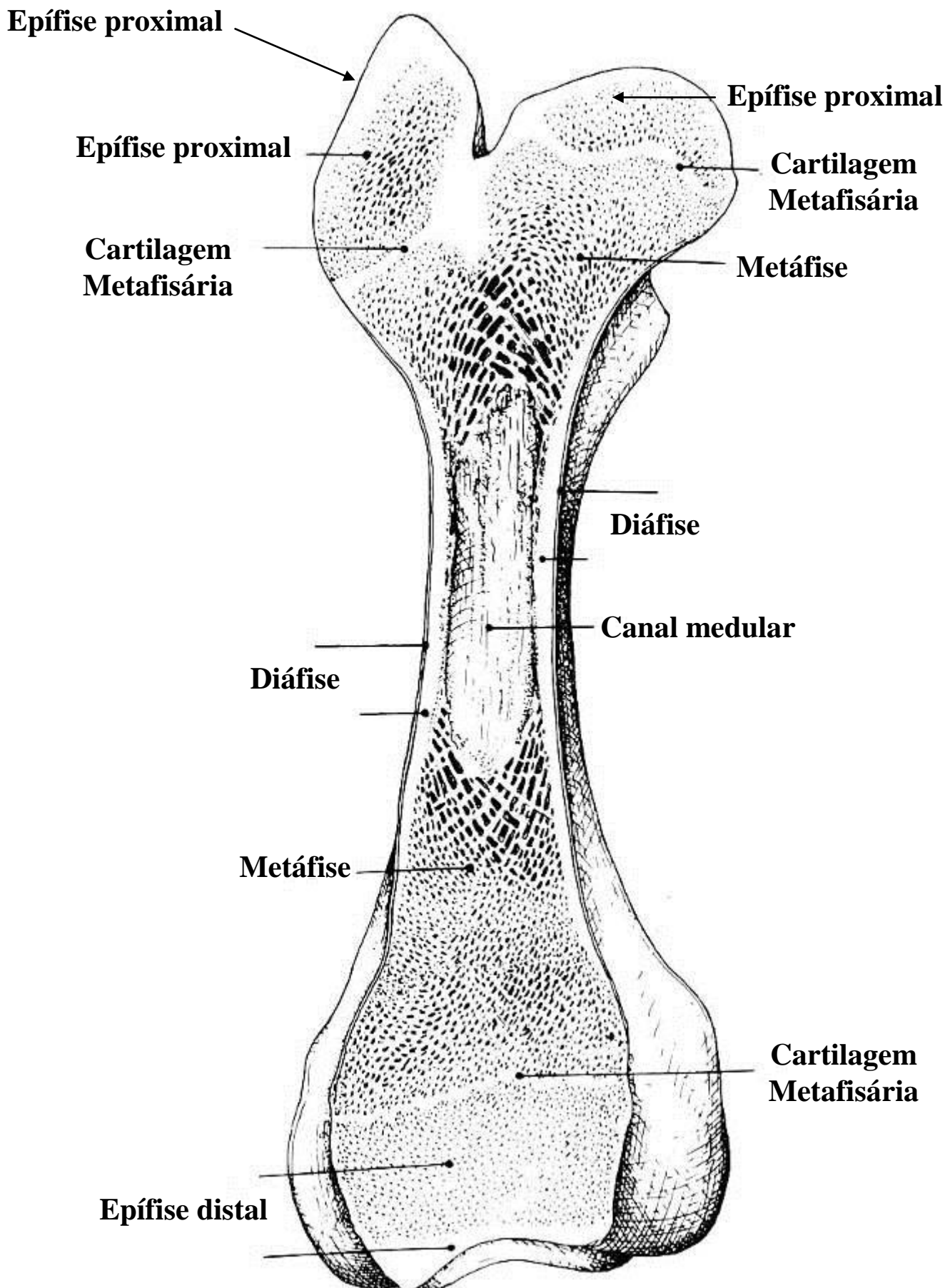
Dê o nome dos ossos apontados a seguir no esqueleto do equino.
Pinte cada osso de uma cor diferente.



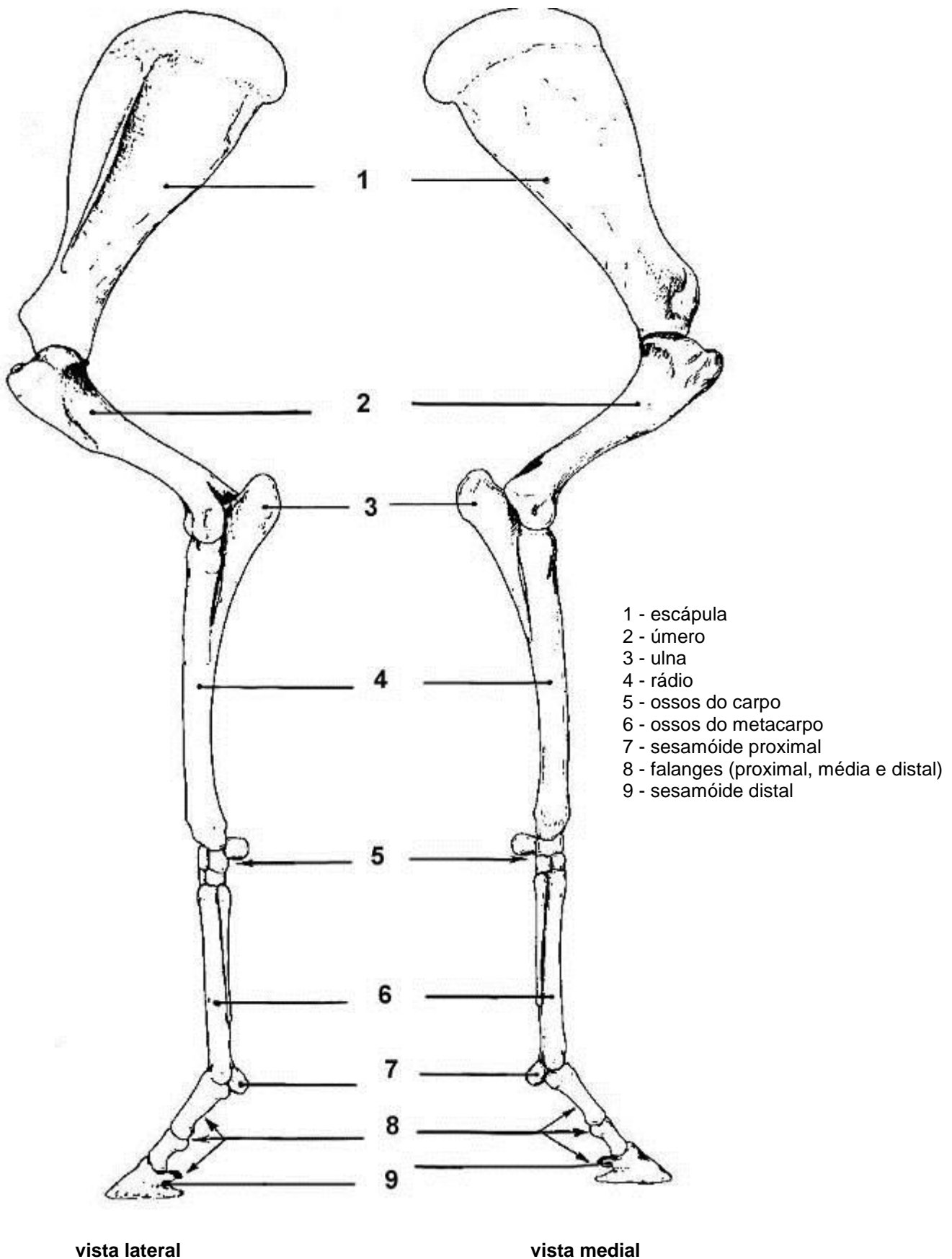
vista lateral

- | | |
|------|------|
| 1 - | 15 - |
| 2 - | 16 - |
| 3 - | 17 - |
| 4 - | 18 - |
| 5 - | 19 - |
| 6 - | 20 - |
| 7 - | 21 - |
| 8 - | 22 - |
| 9 - | 23 - |
| 10 - | 24 - |
| 11 - | 25 - |
| 12 - | 26 - |
| 13 - | 27 - |
| 14 - | |

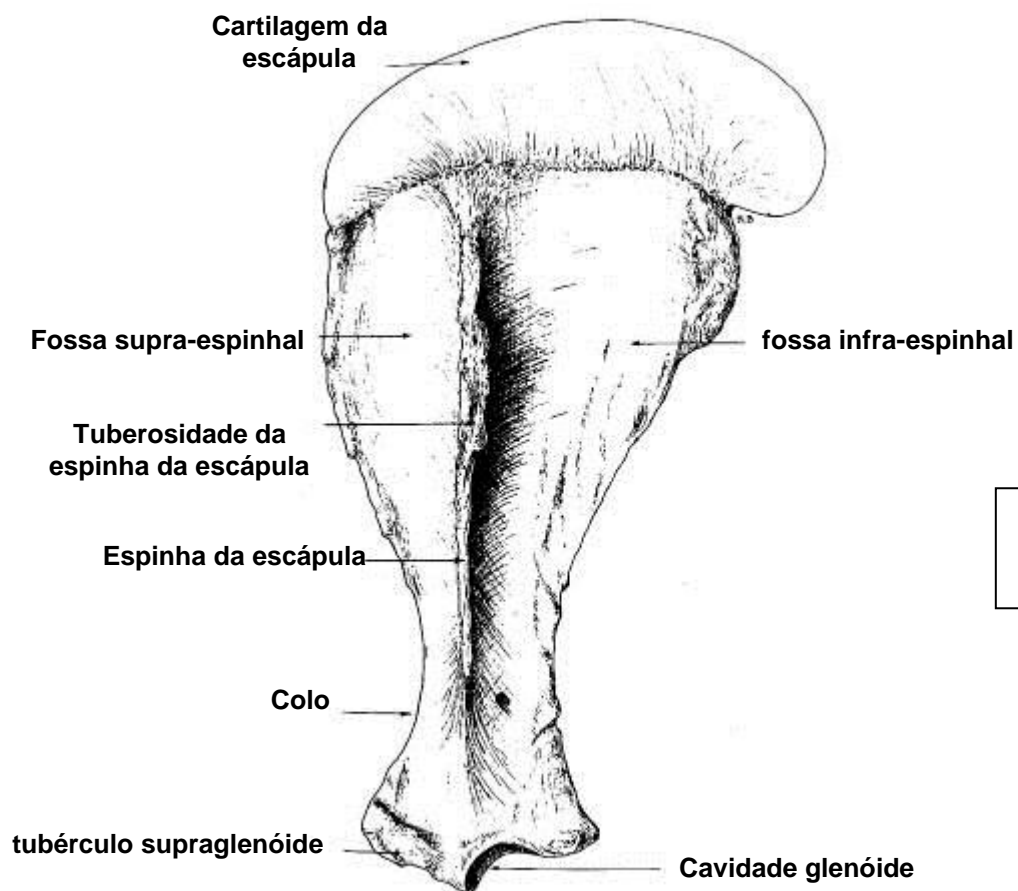
ESTRUTURA DO OSSO LONGO



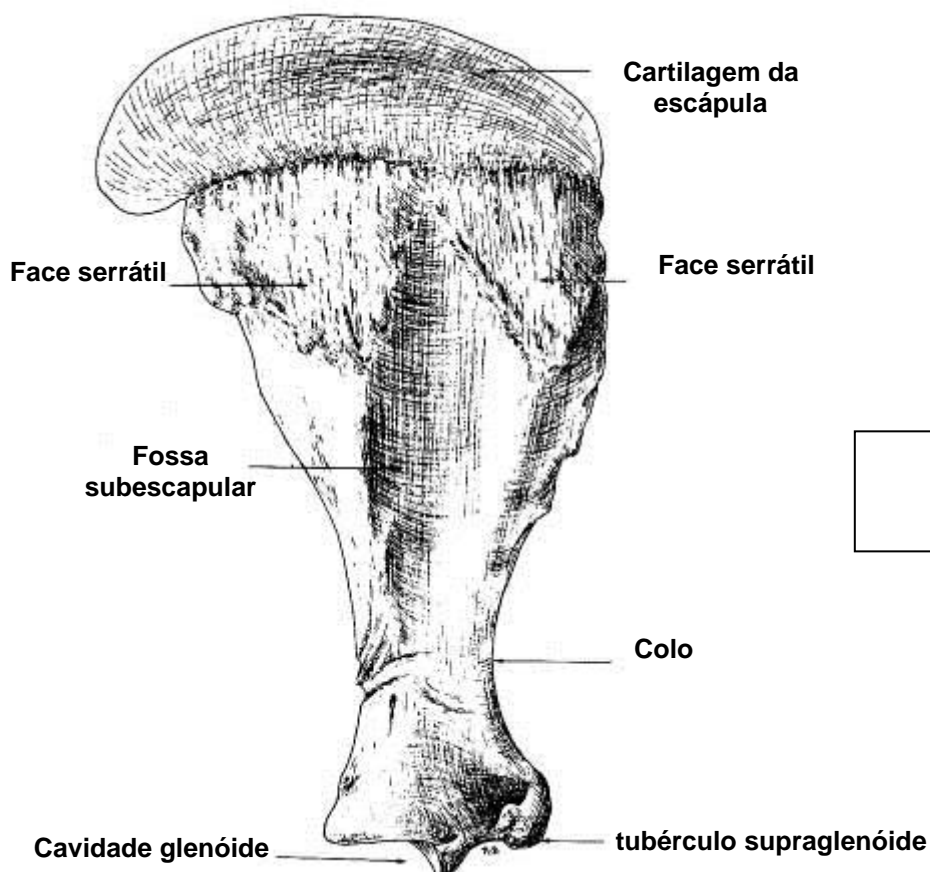
OSSOS DO MEMBRO TORÁCICO



ESCÁPULA

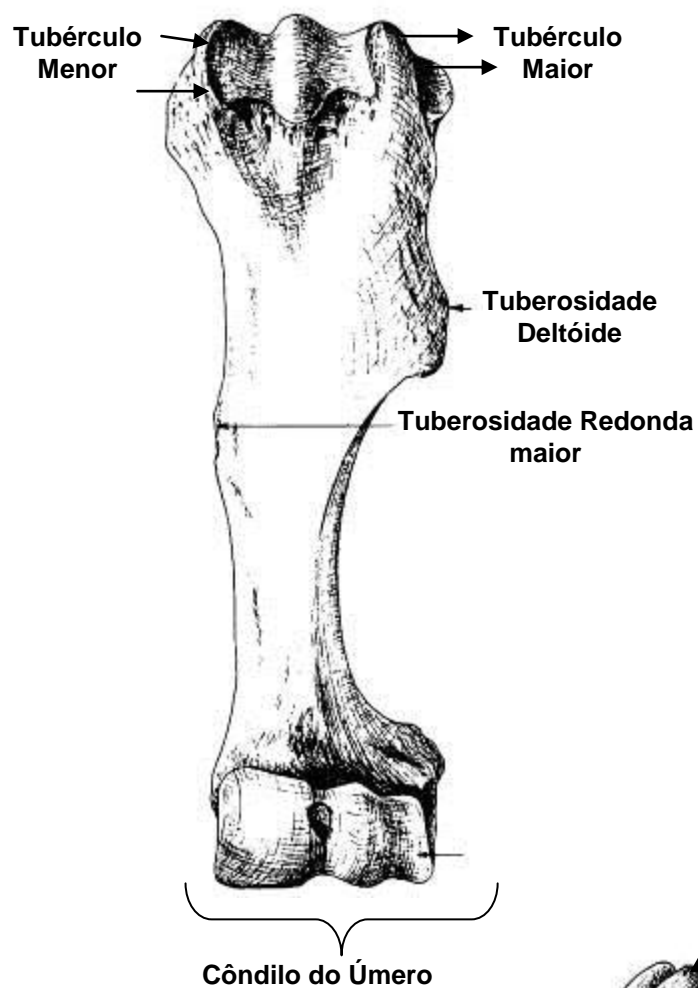


**Vista
Lateral**

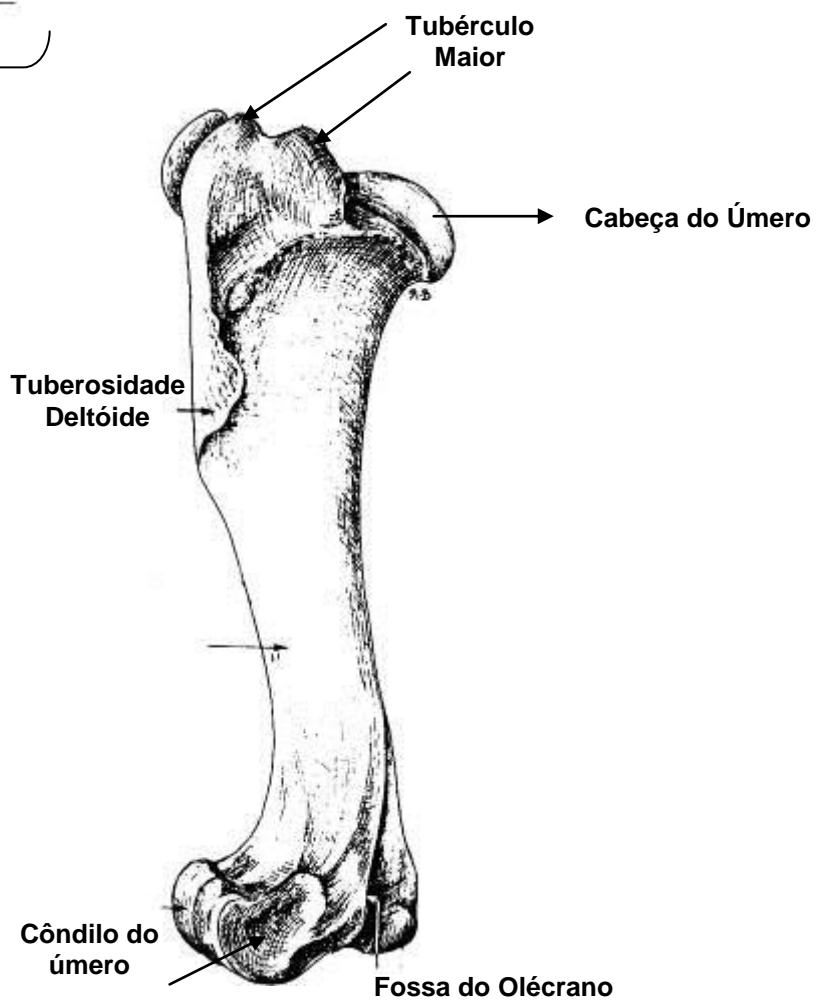


**Vista
Medial**

ÚMERO

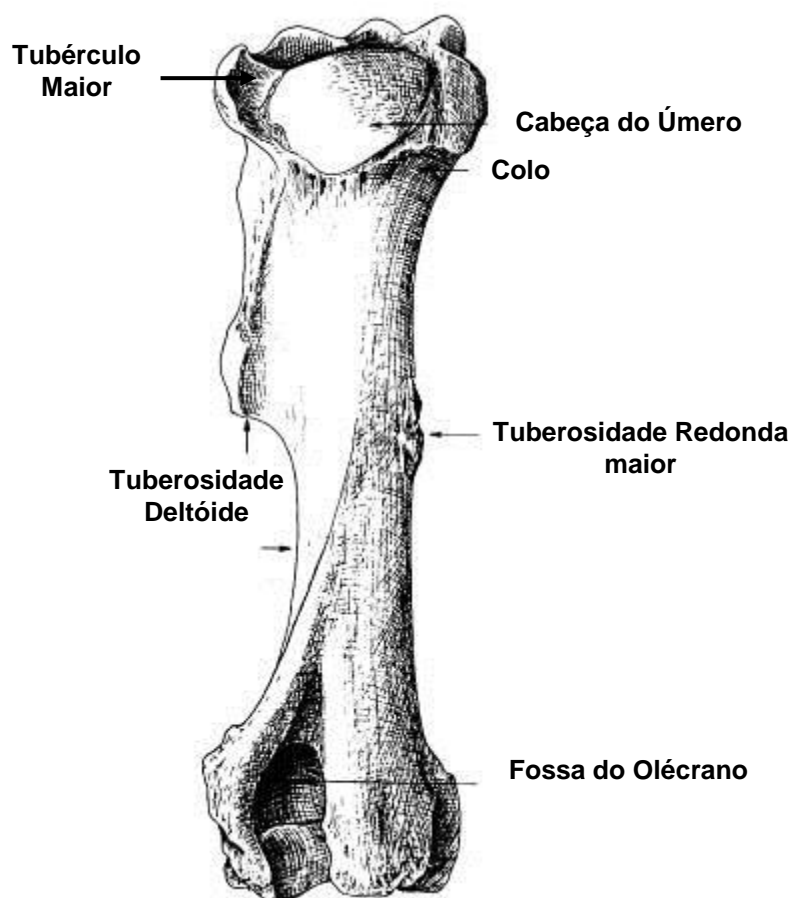


Vista Cranial

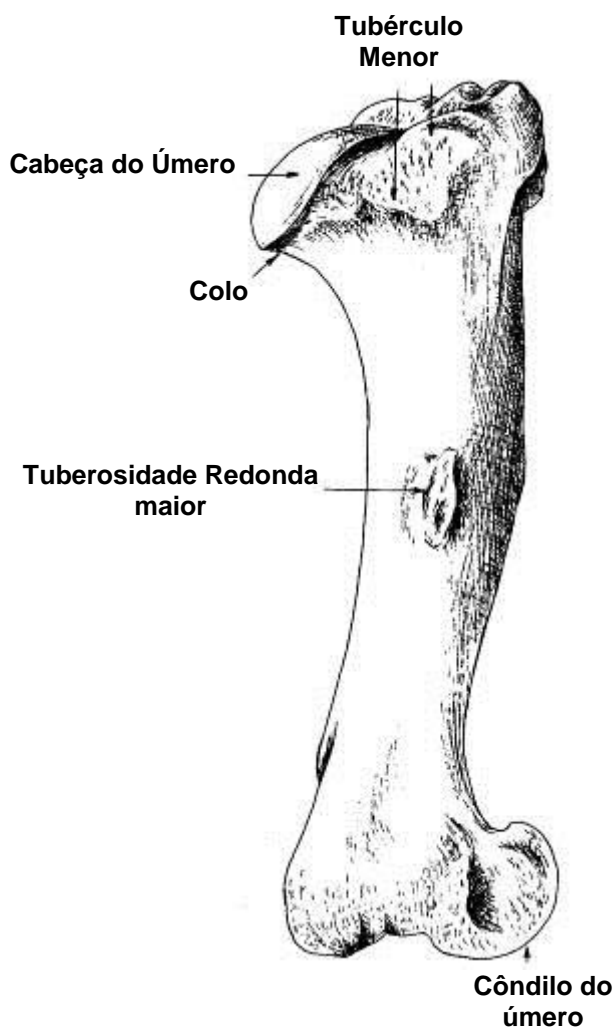


Vista Lateral

ÚMERO



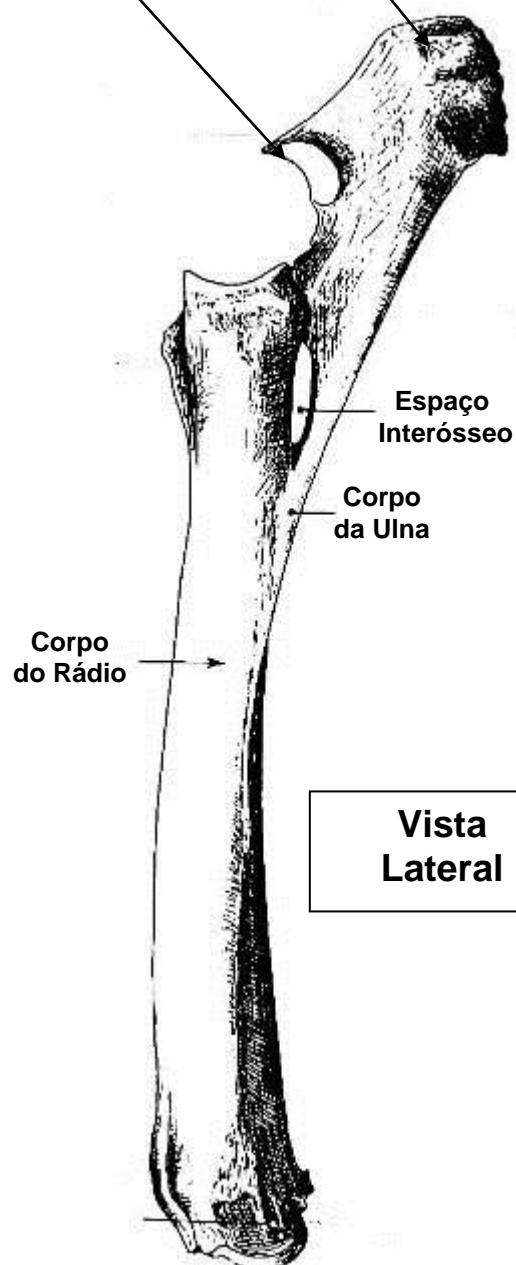
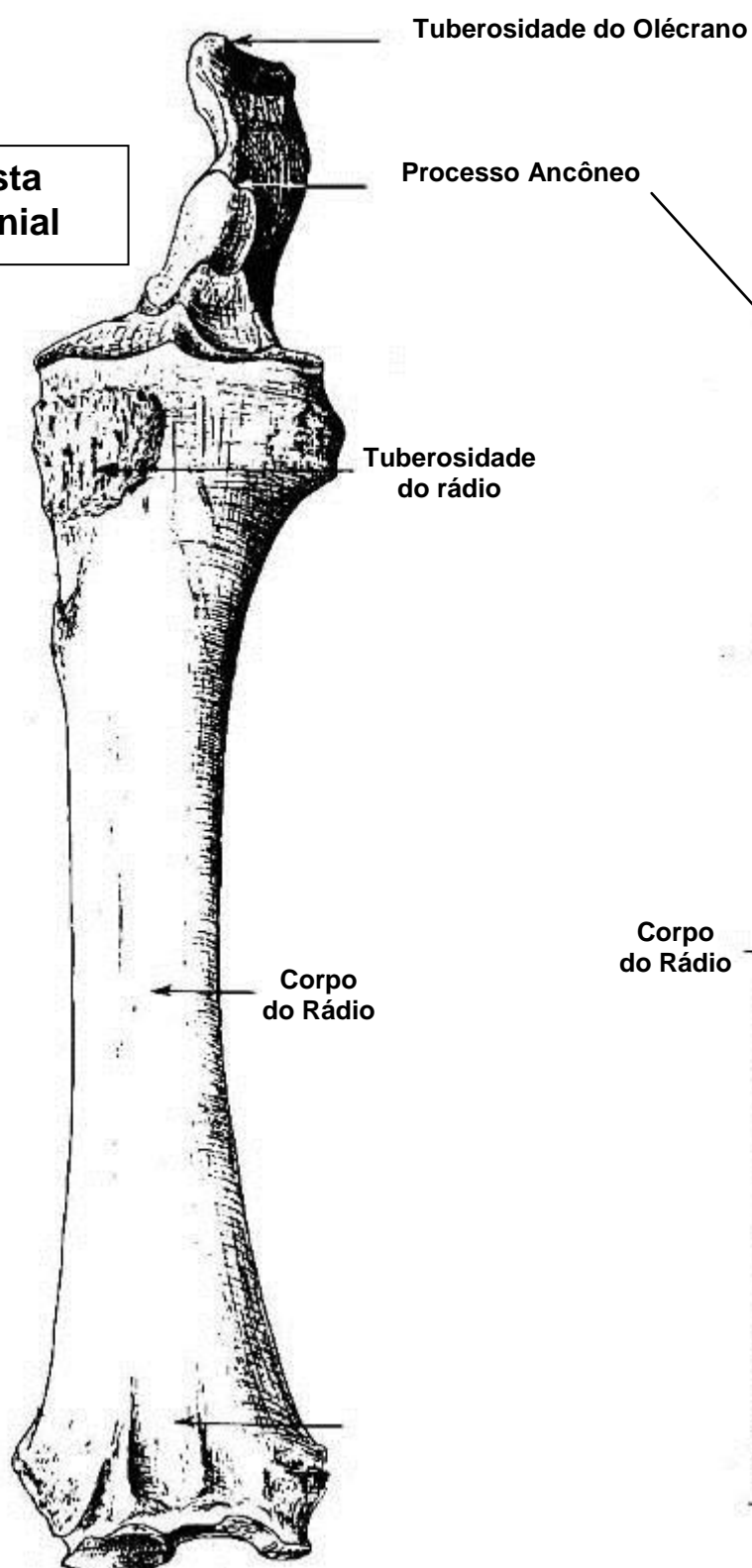
Vista Caudal



Vista Medial

RÁDIO e ULNA

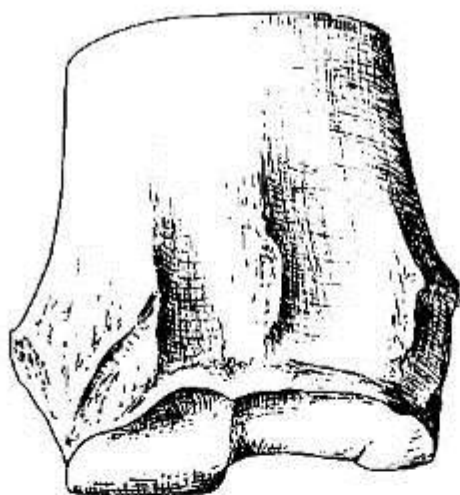
**Vista
Cranial**



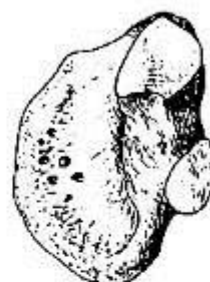OSSOS DO CARPO

VISTA CRANIAL OU DORSAL

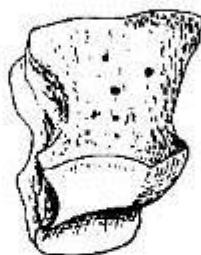
extremidade distal do rádio



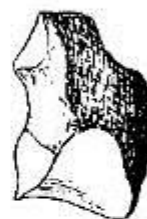osso carpo
acessório



osso carpo
intermédio



osso carpo
ulnar




osso carpo
radial



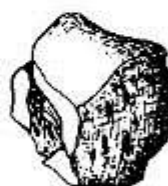II osso
cárpico



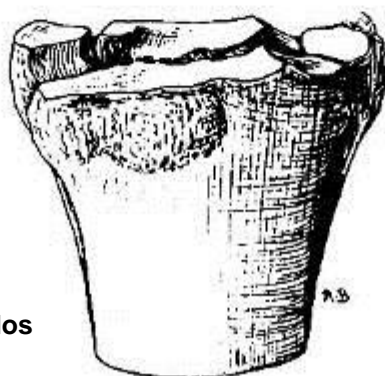
III osso
cárpico



IV osso
cárpico

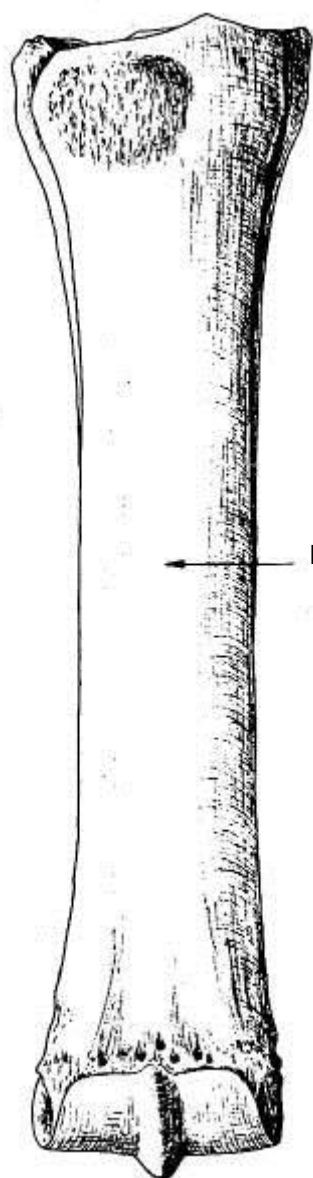


extremidade proximal dos
ossos do metacarpo

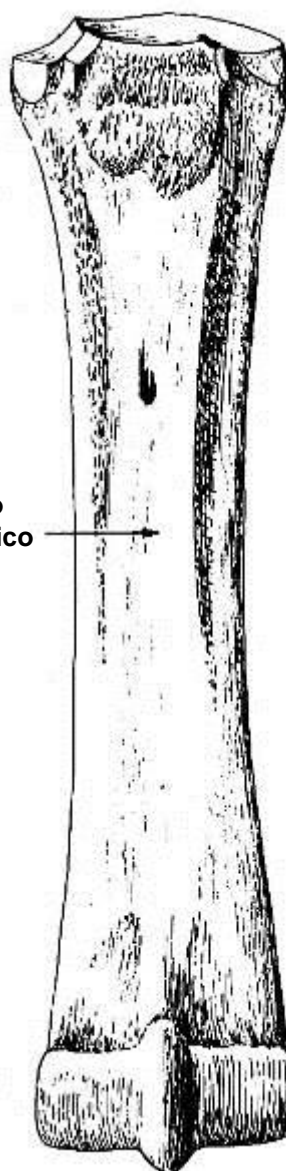


Metacarpos

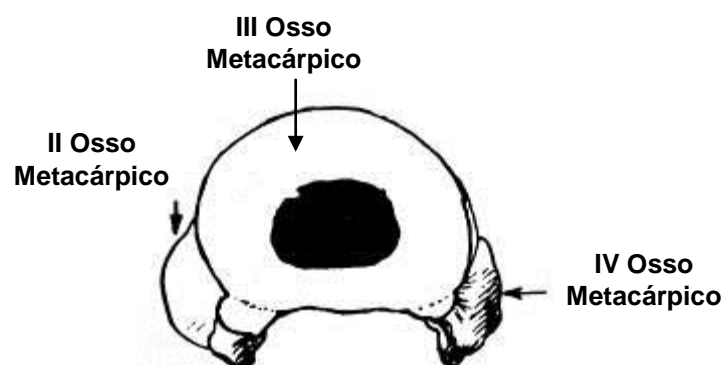
OSSO METACARPO



vista dorsal

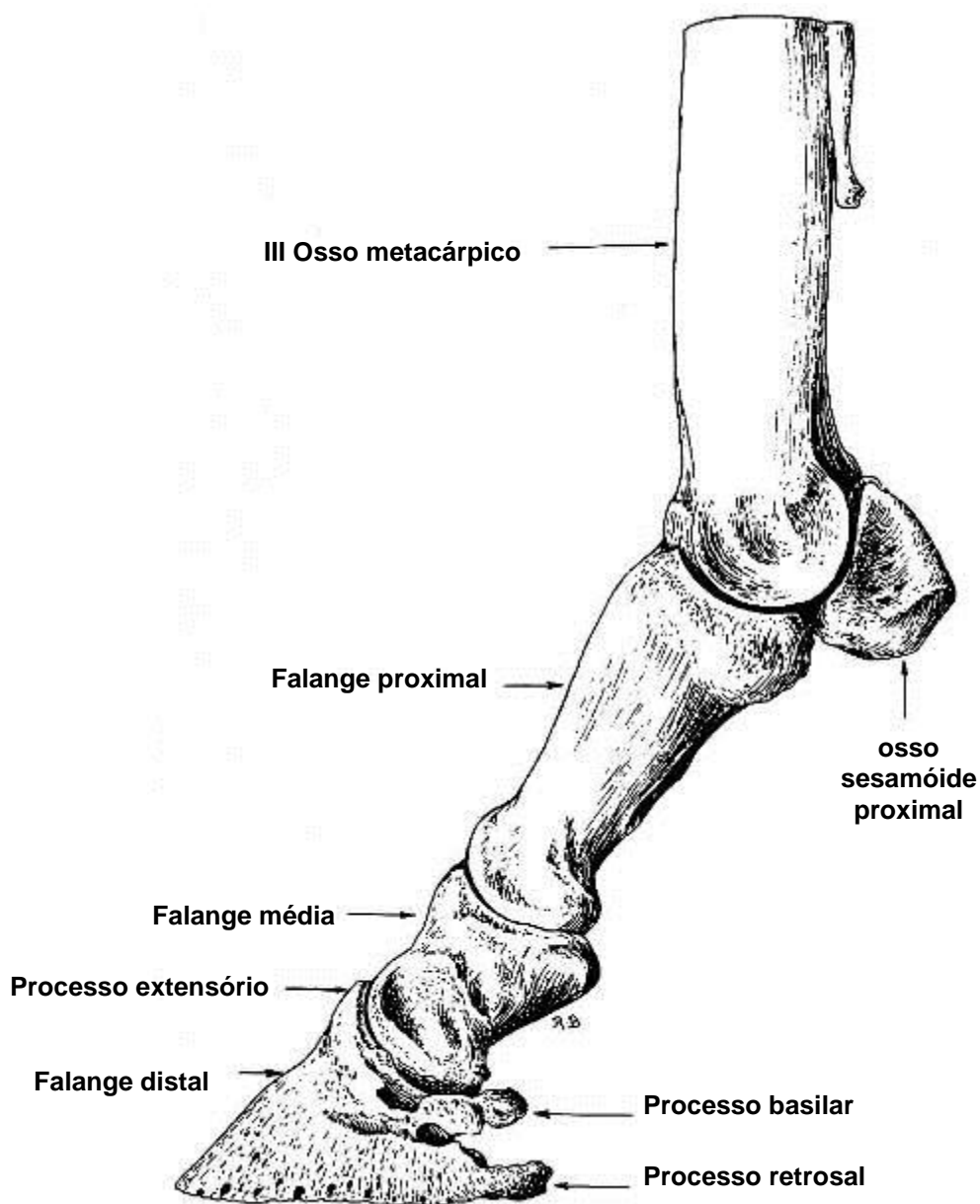


vista palmar



secção transversal proximal dos ossos metacarpícos

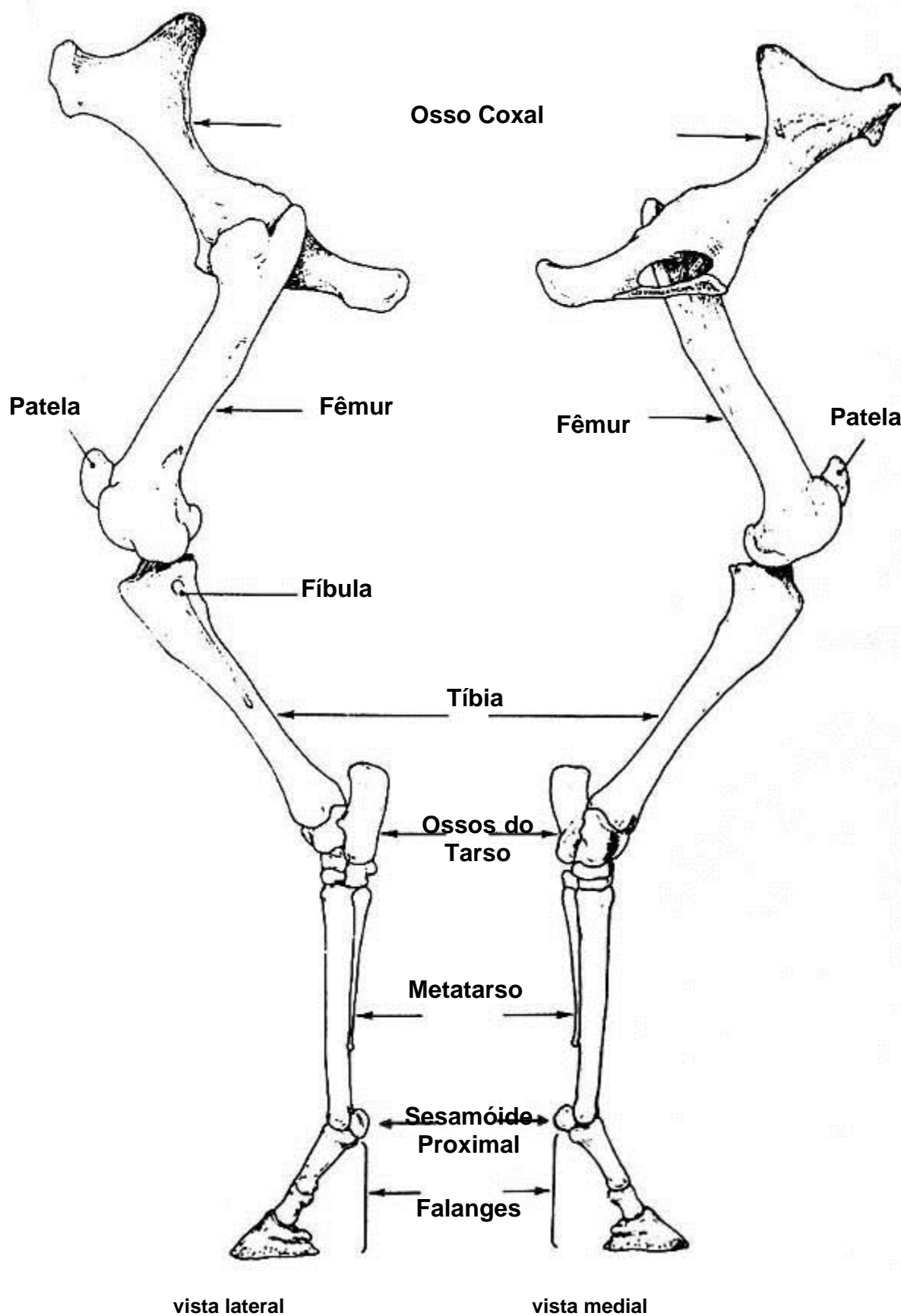
OSSOS DOS DÍGITOS DOS MEMBROS TORÁCICO e PÉLVICO



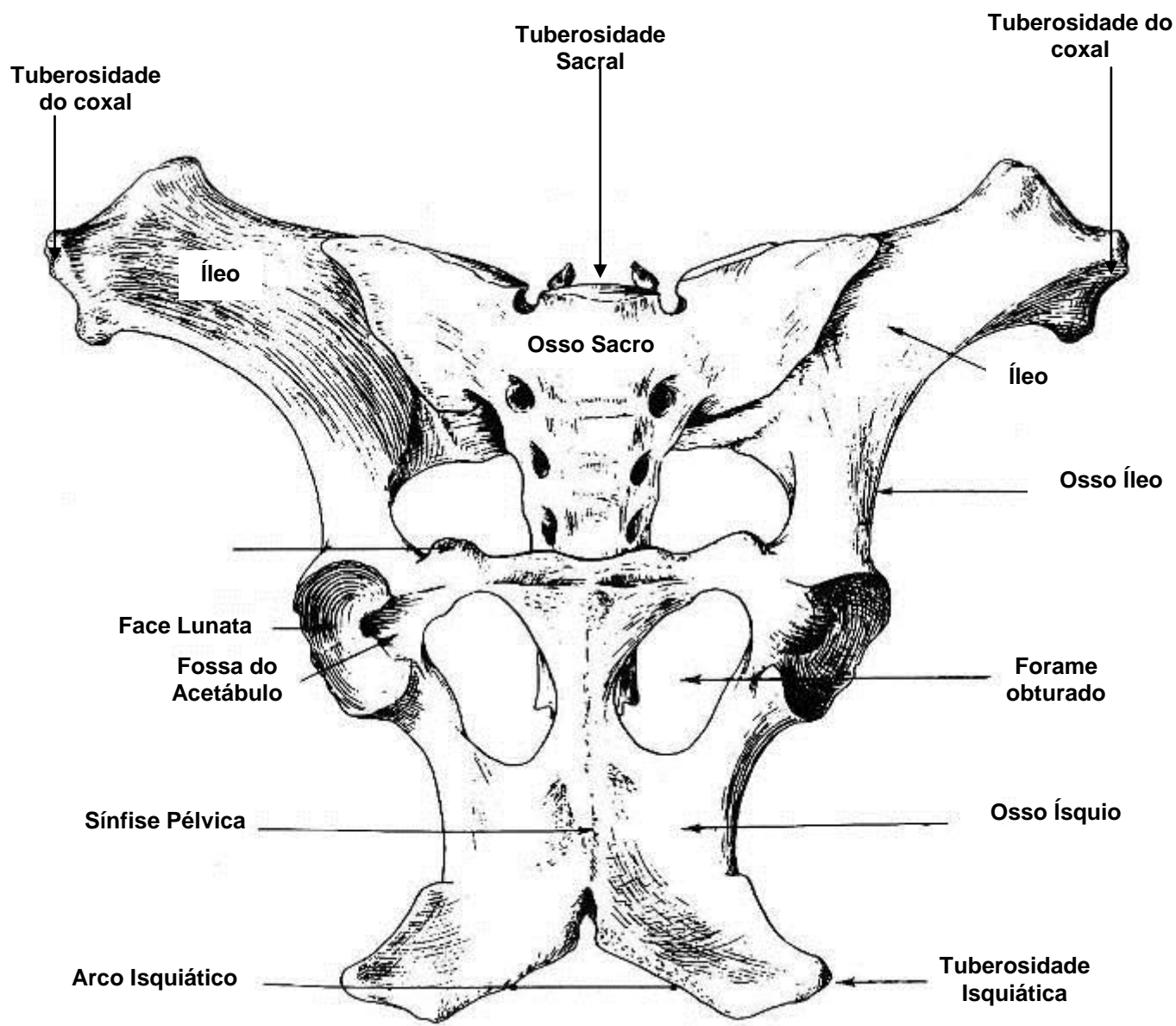
**Vista
Lateral**

Obs.: O **osso sesamóide distal (navicular)** não pode ser visualizado.
Ele localiza-se caudalmente entre a falange média e a falange distal

MEMBRO PÉLVICO

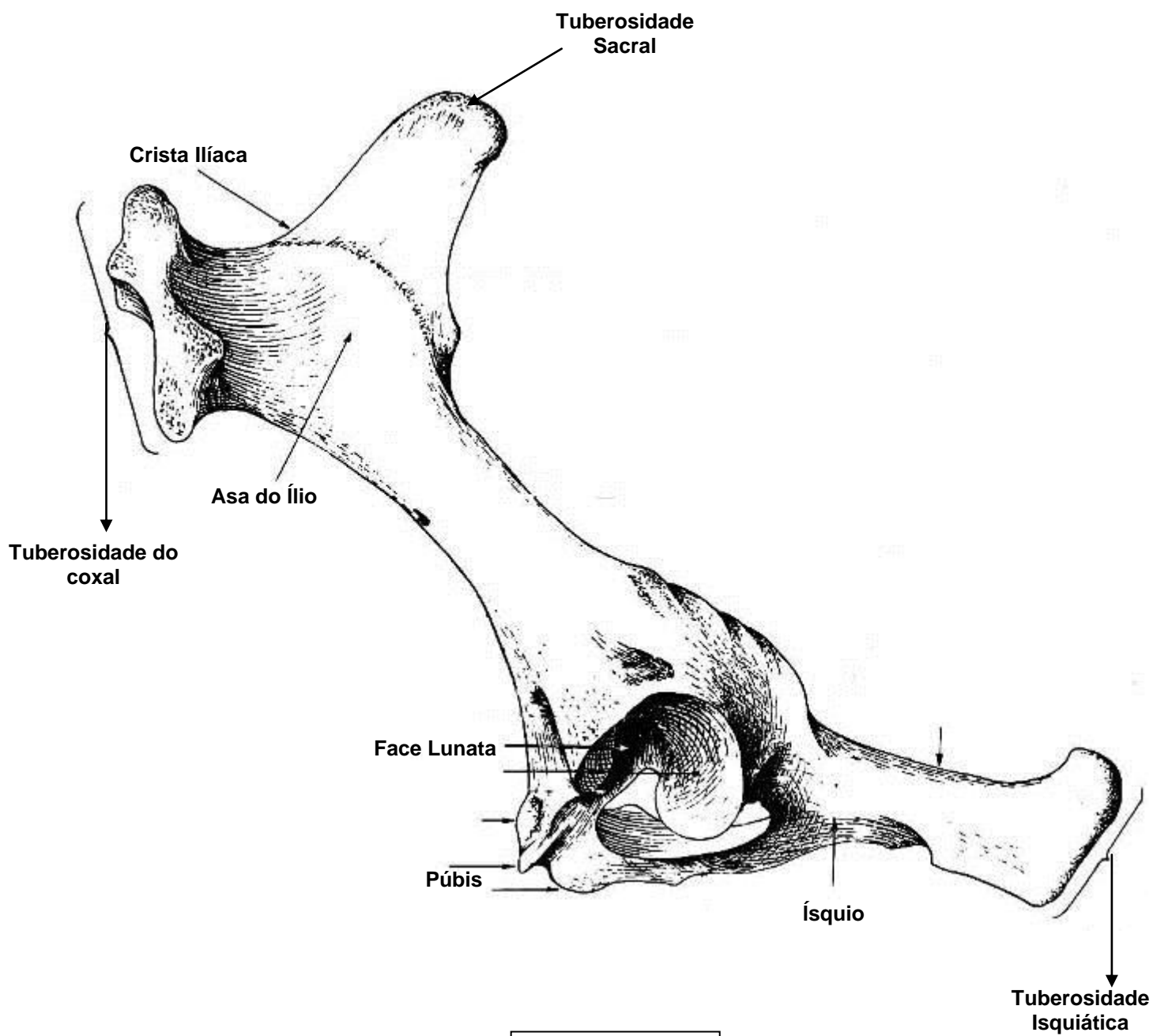


OSSO COXAL



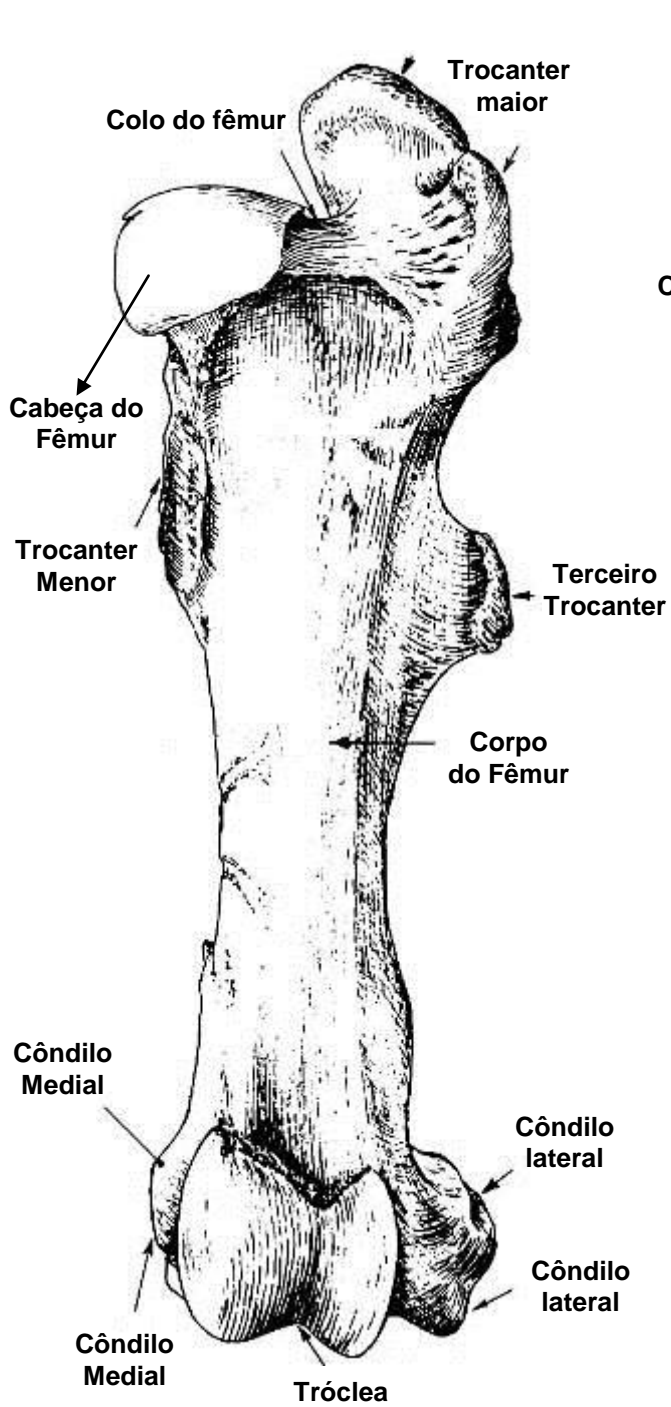
**Vista
Ventral**

OSSO COXAL

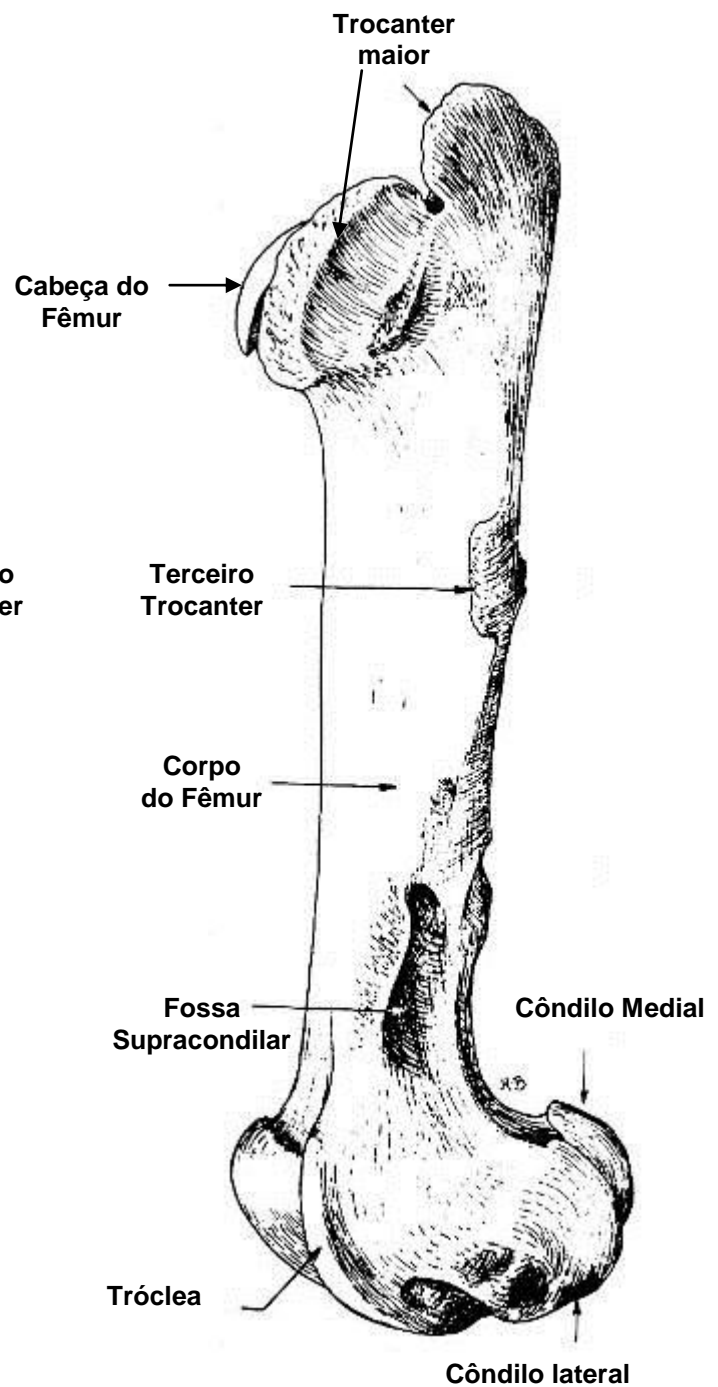


**Vista
Lateral**

FÊMUR

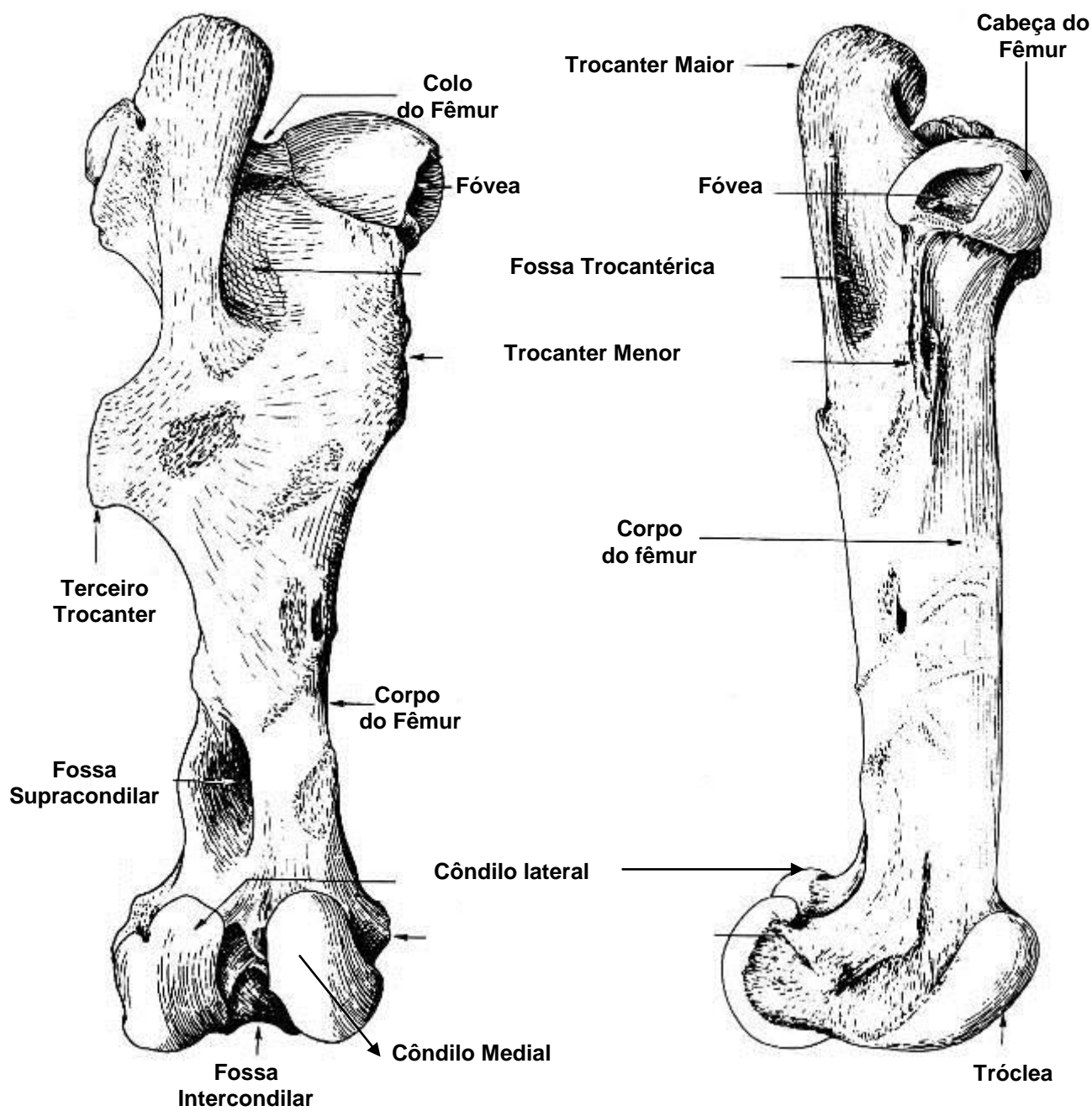


**Vista
Cranial**



**Vista
Lateral**

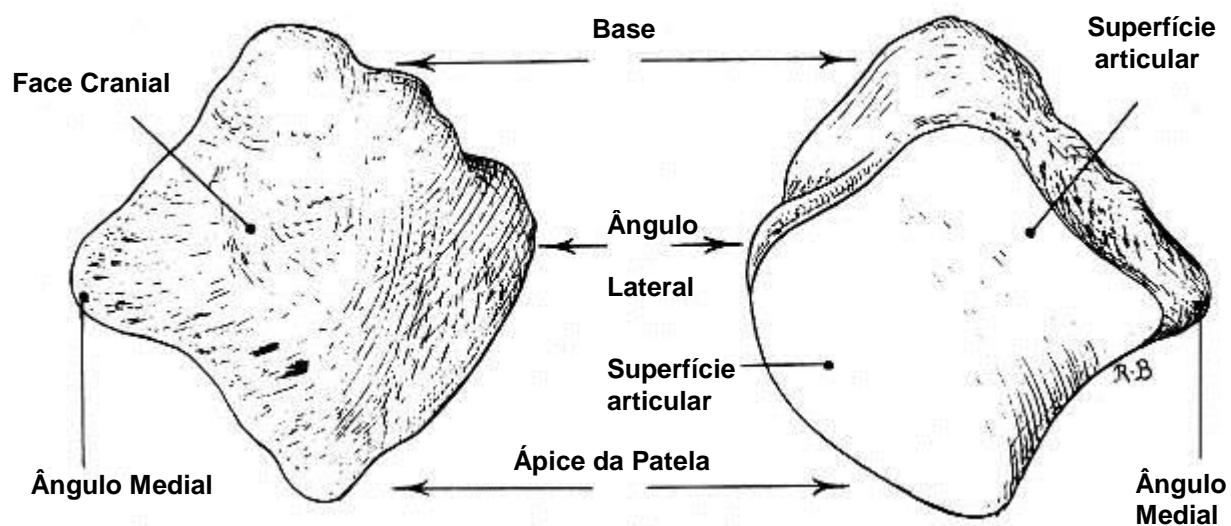
FÊMUR



**Vista
Caudal**

**Vista
Medial**

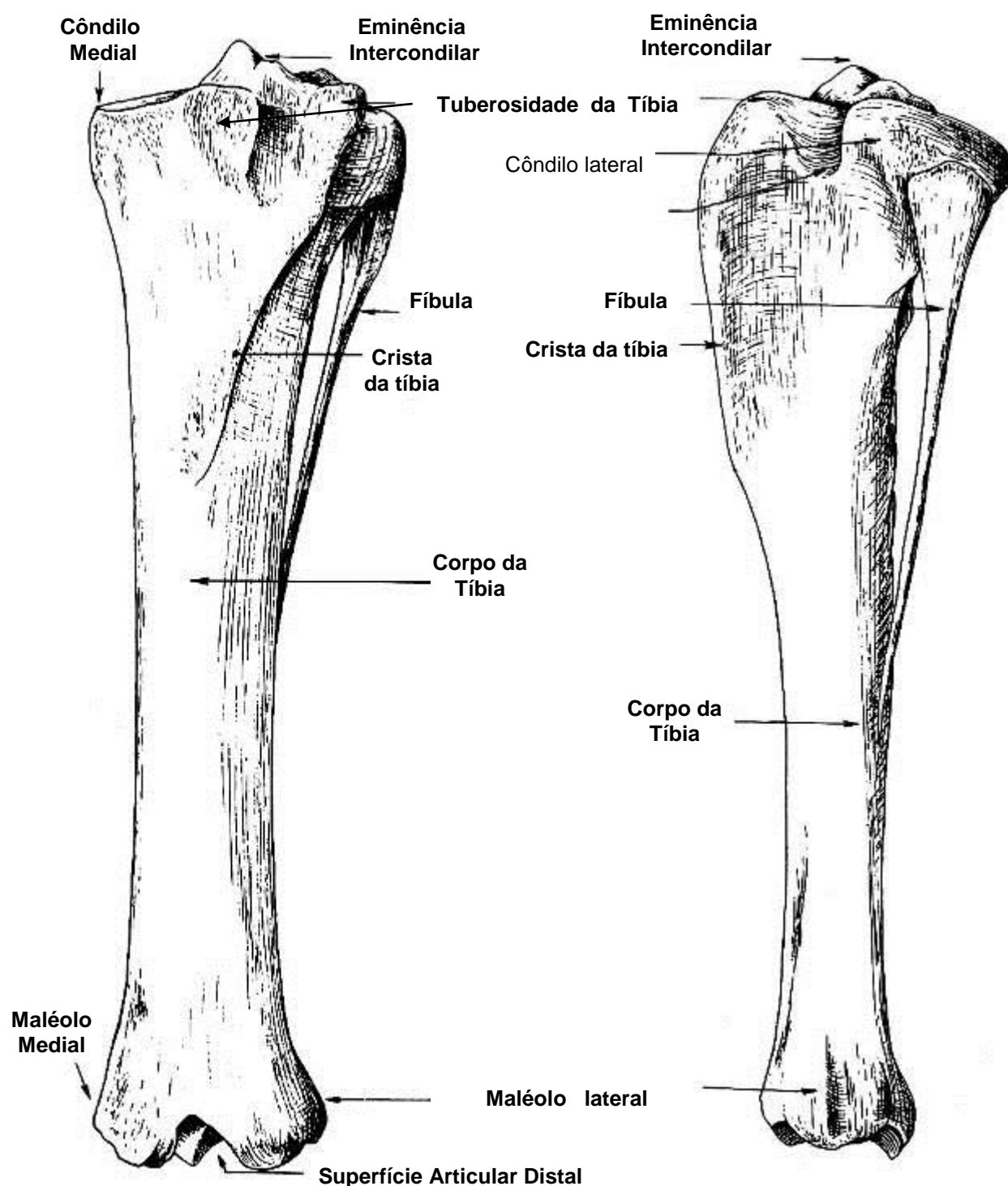
Patela



**Vista
Cranial**

**Vista
Caudal**

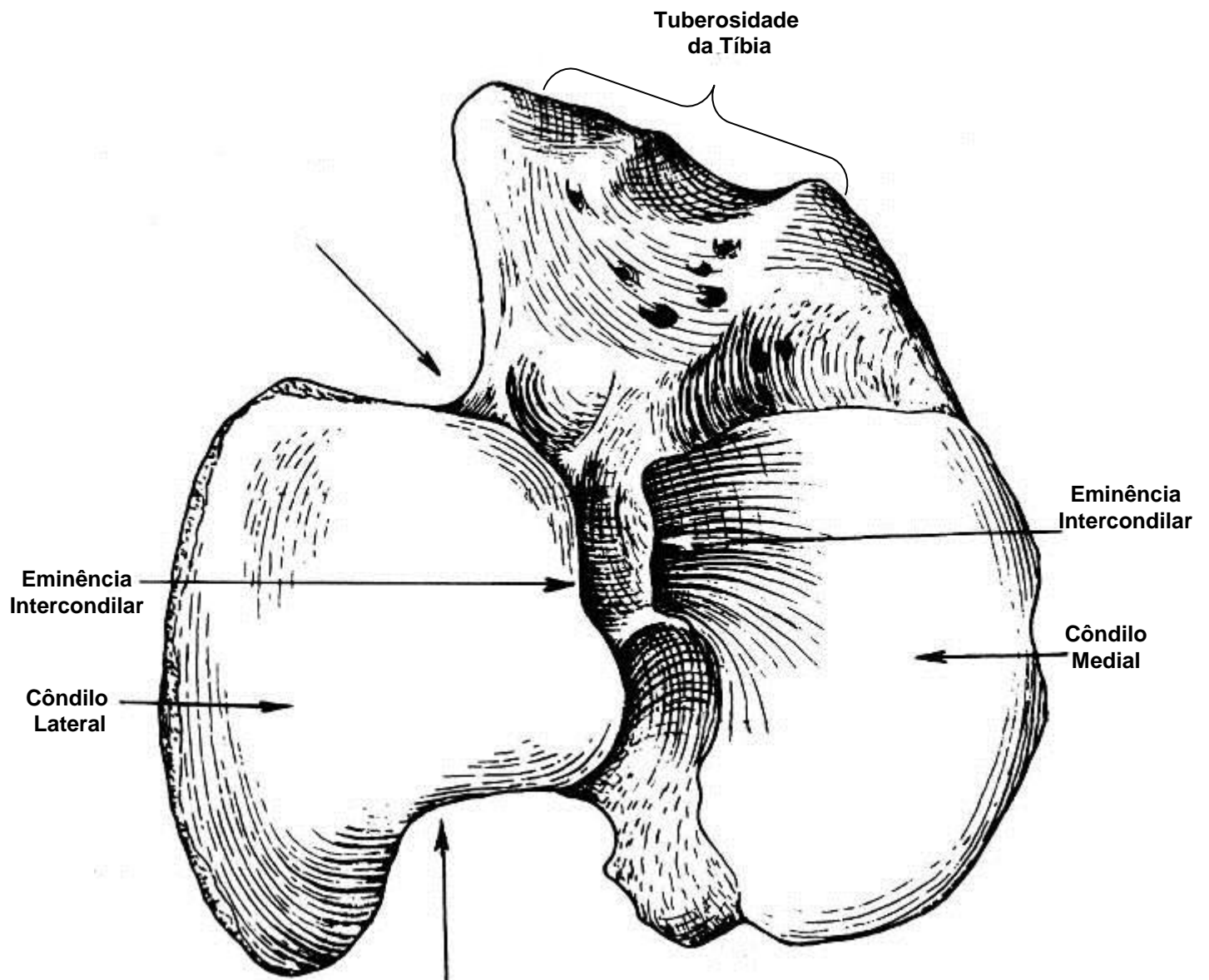
TÍBIA e FÍBULA



**Vista
Cranial**

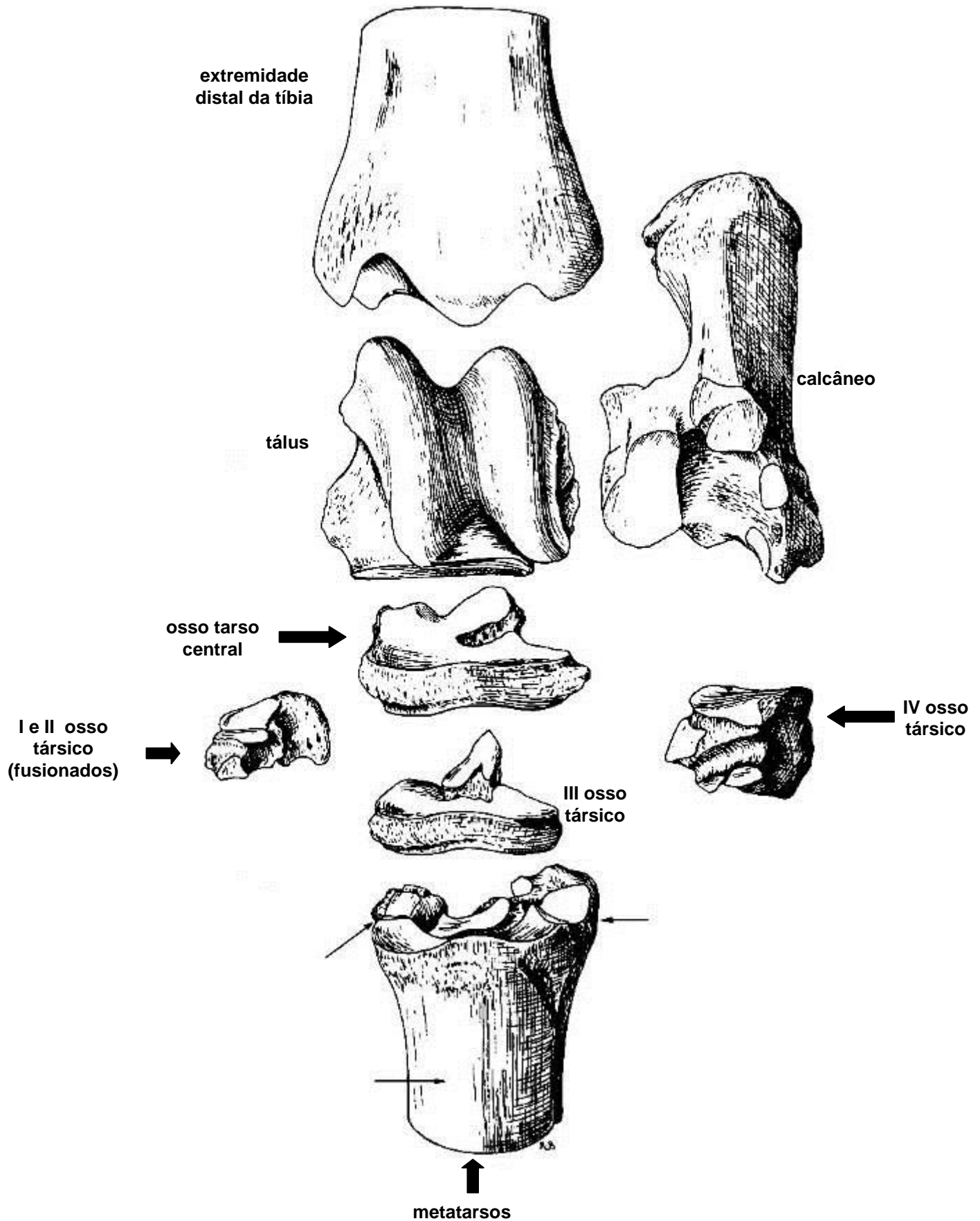
**Vista
Lateral**

TÍBIA e FÍBULA

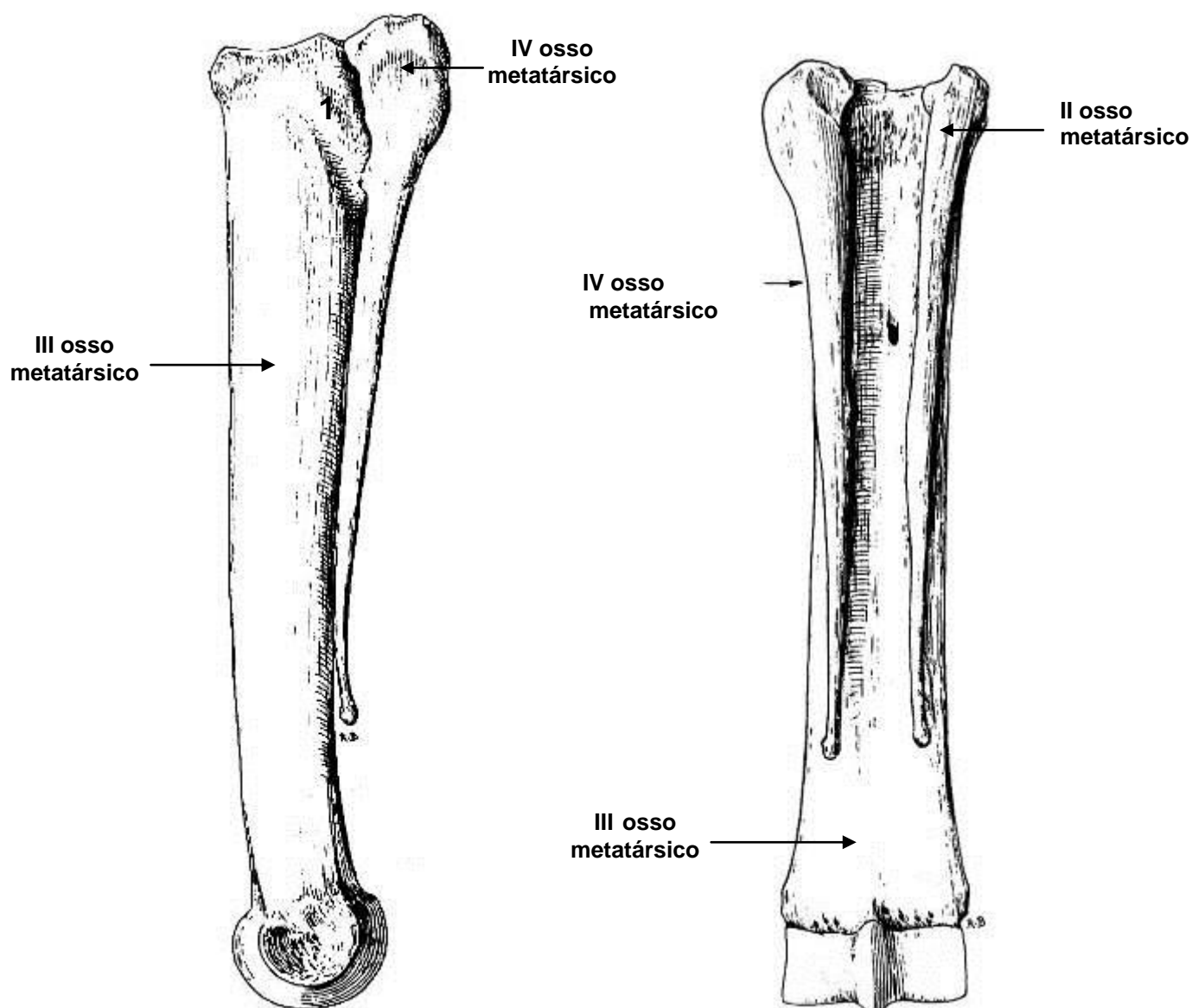


**Vista
Dorsal**

OSSOS DO TARSO

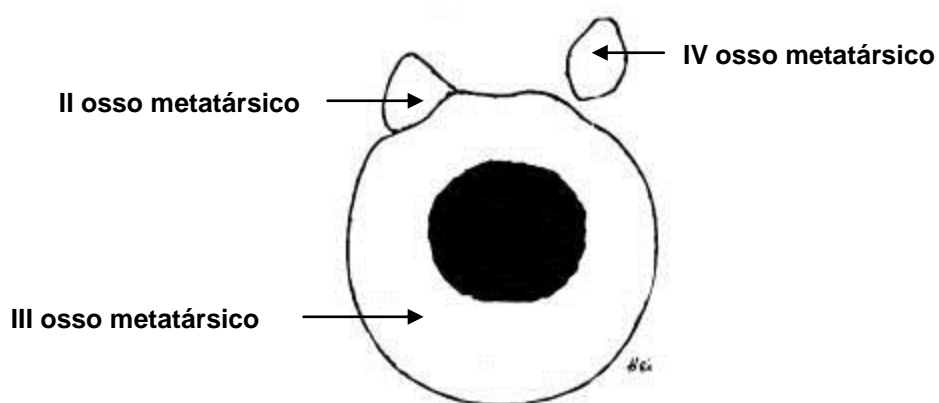


OSSO METATARSO



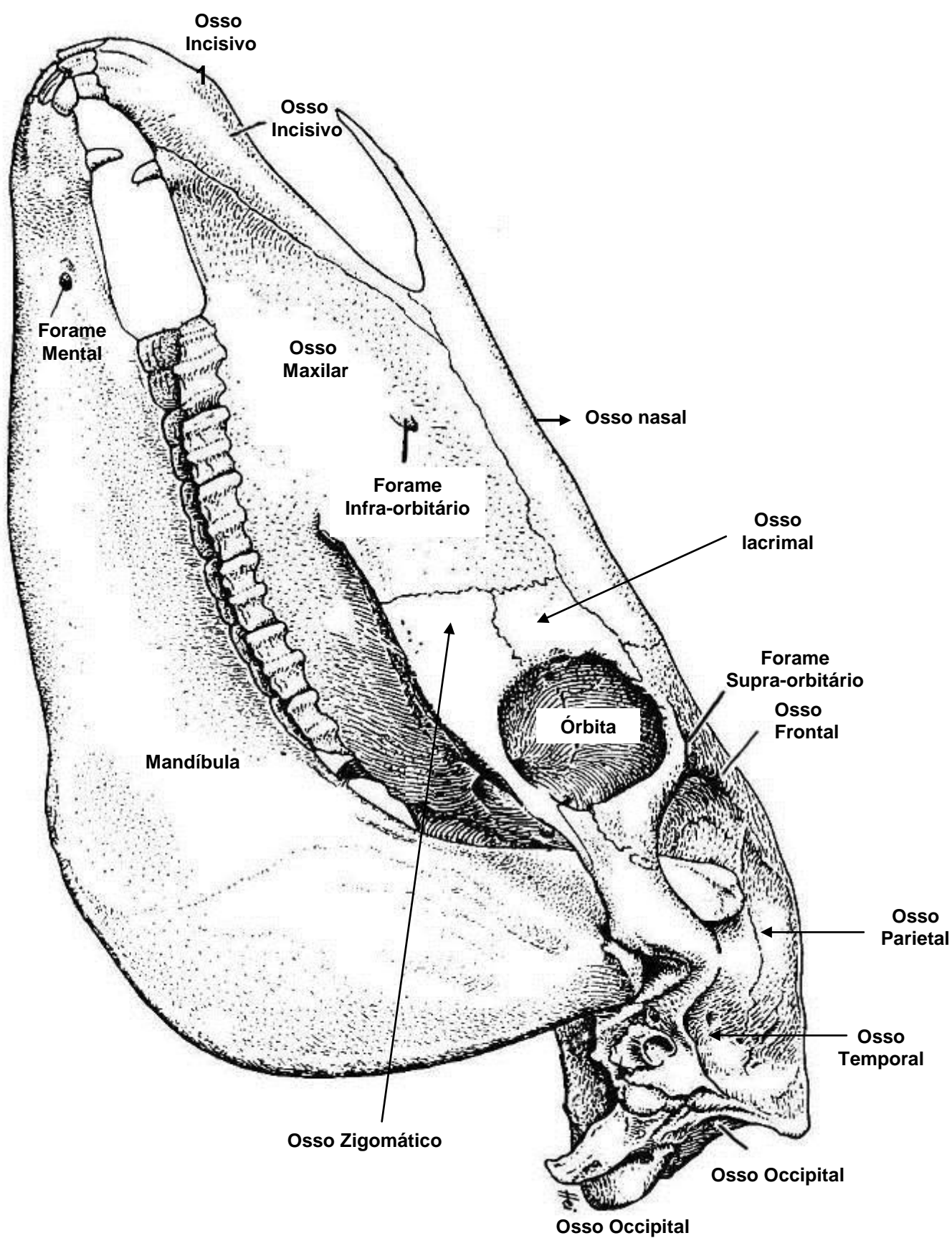
vista lateral

vista plantar

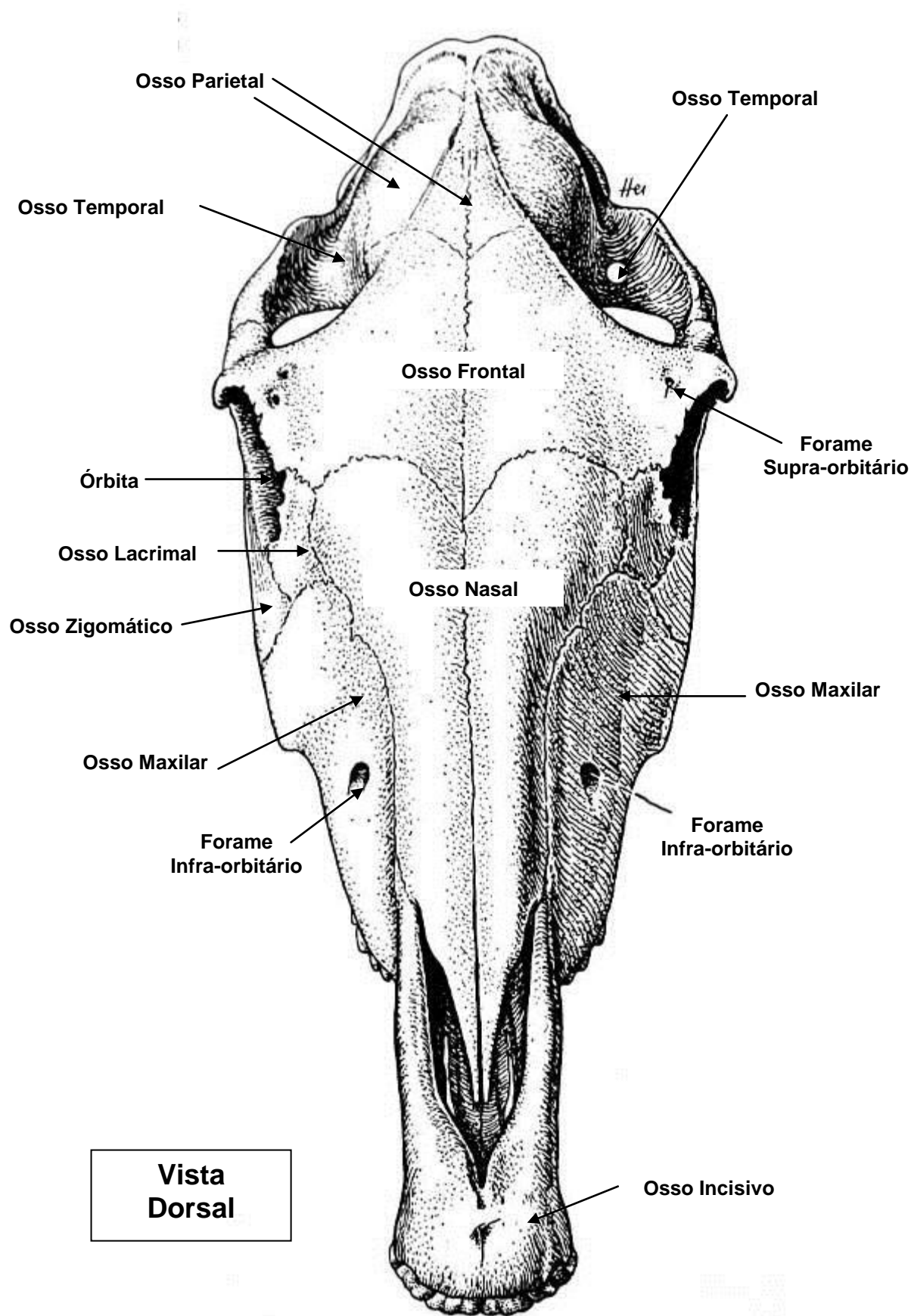


secção transversal proximal dos ossos metatársicos

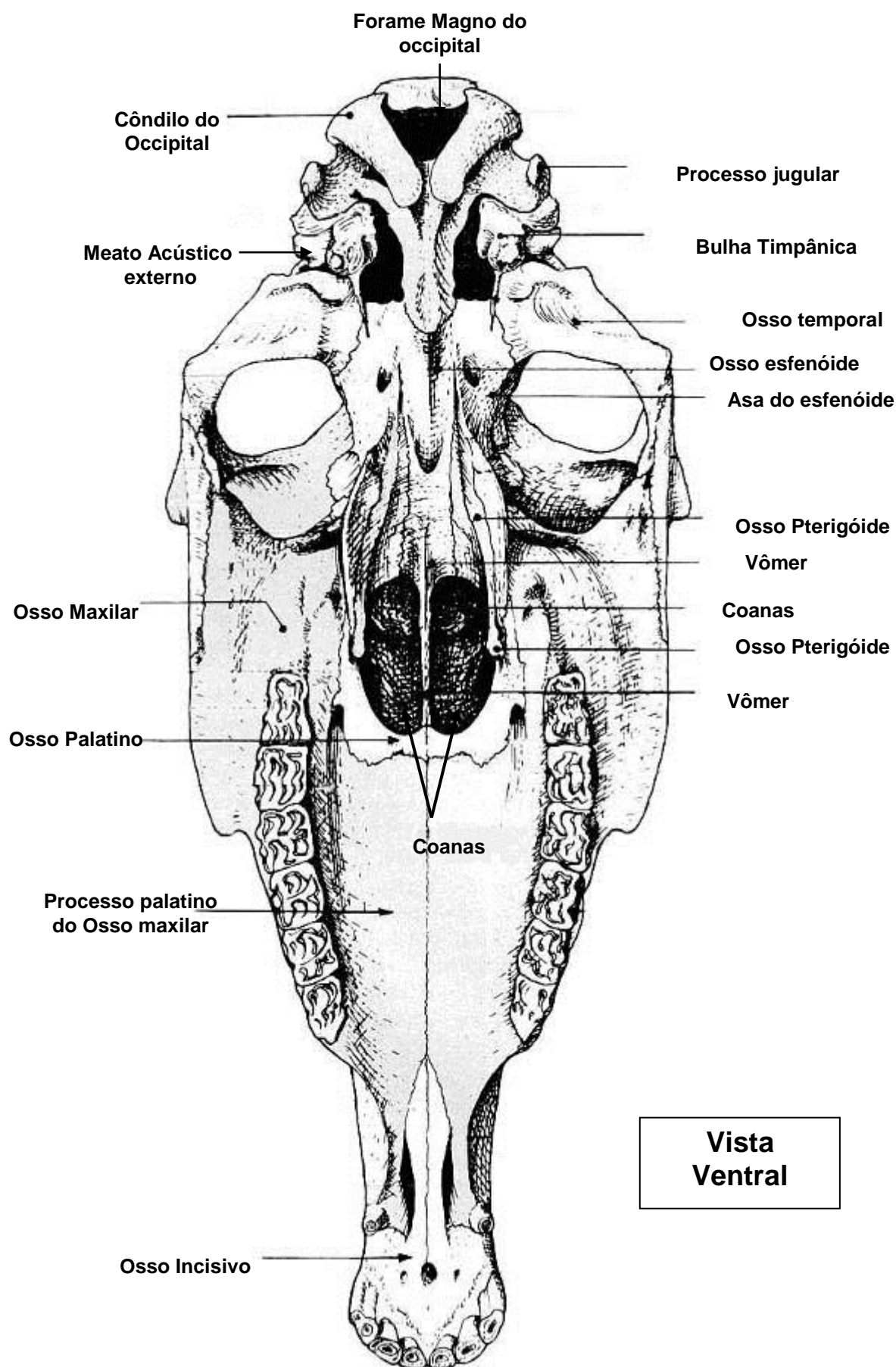
OSSO DA CABEÇA (crânio e face) DO EQUINO



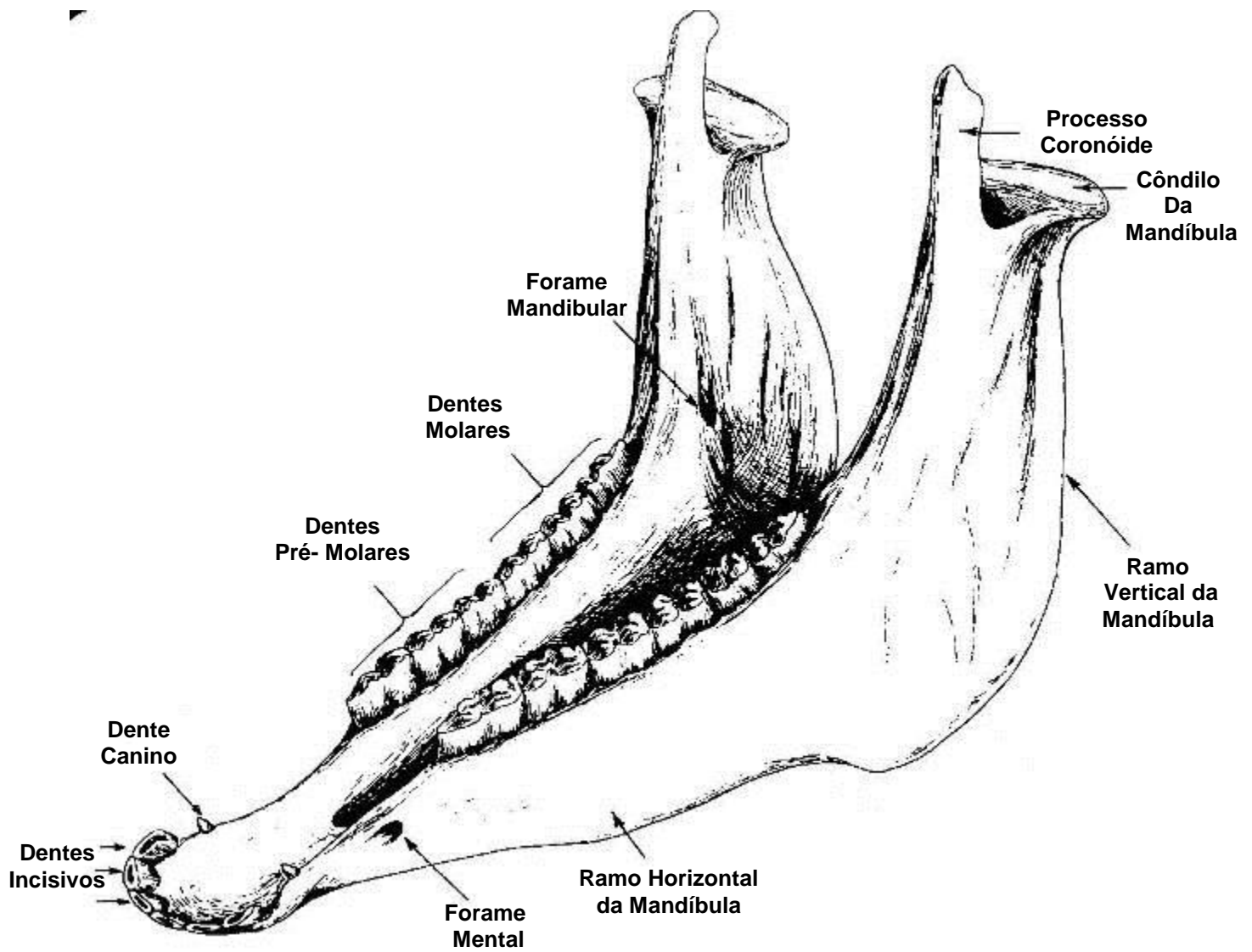
OSSO DA CABEÇA (crânio e face) DO EQUINO



OSSO DA CABEÇA (crânio e face) DO EQUINO

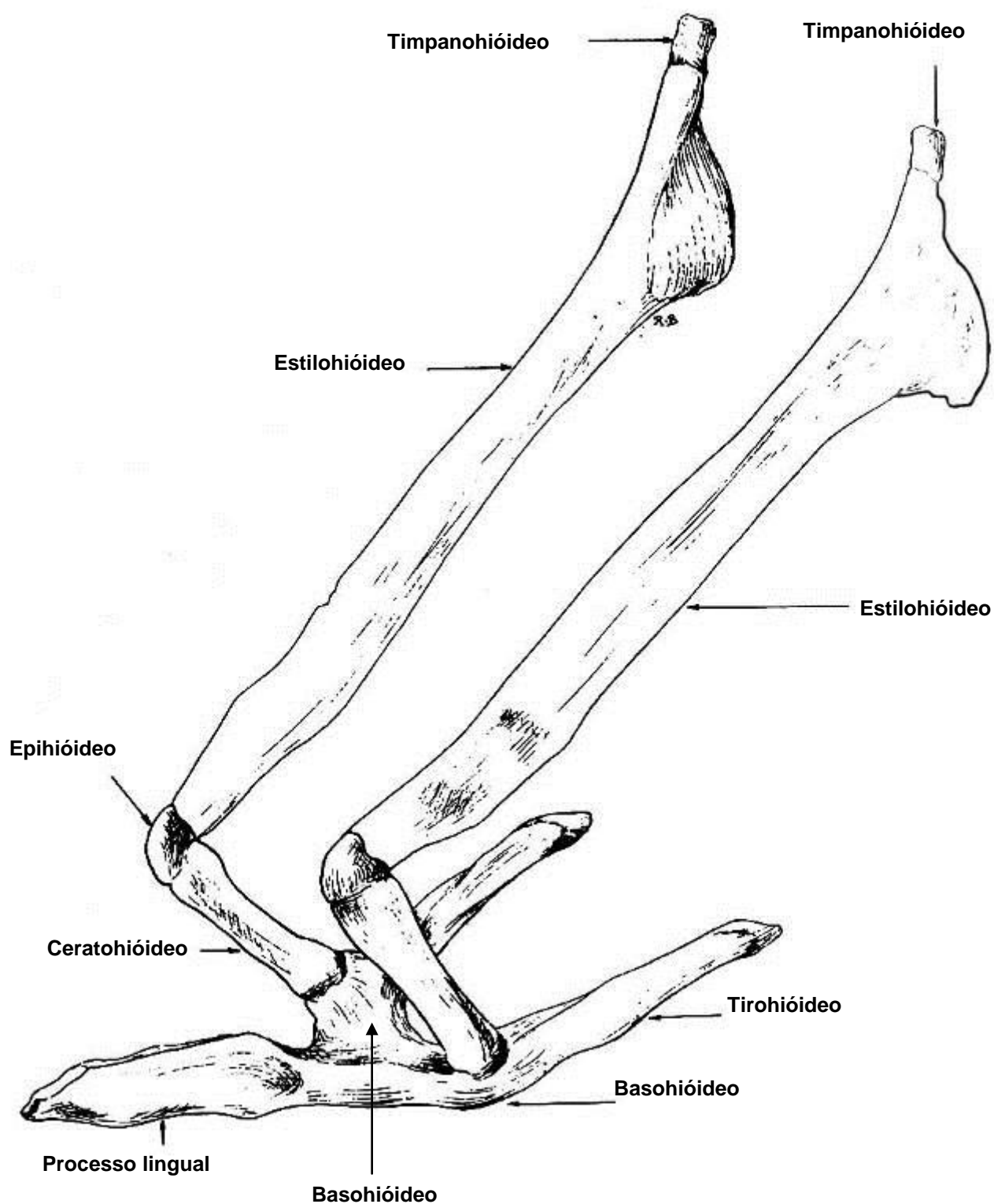


Mandíbula



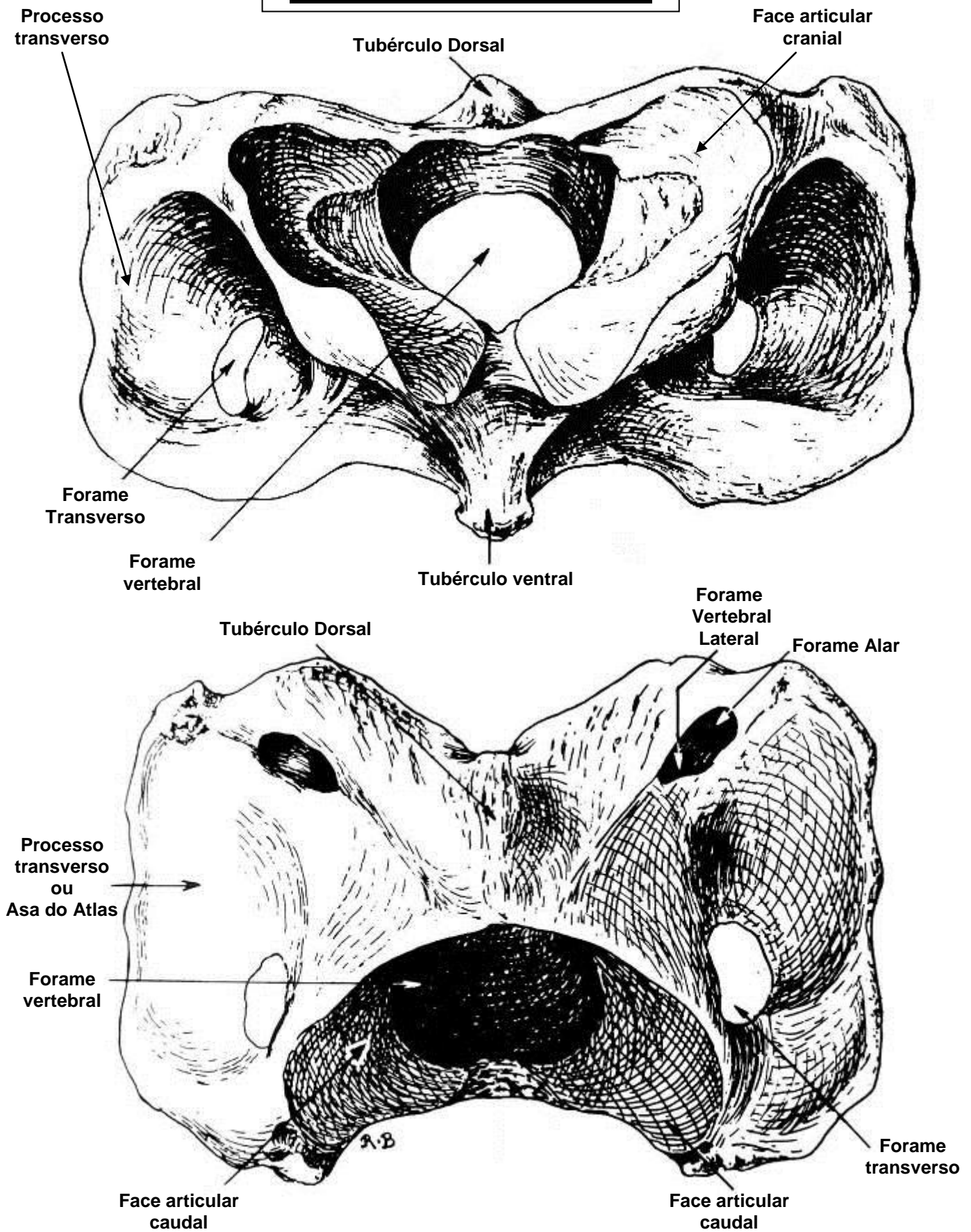
Vista Crânio-lateral

APARELHO HIÓIDEO

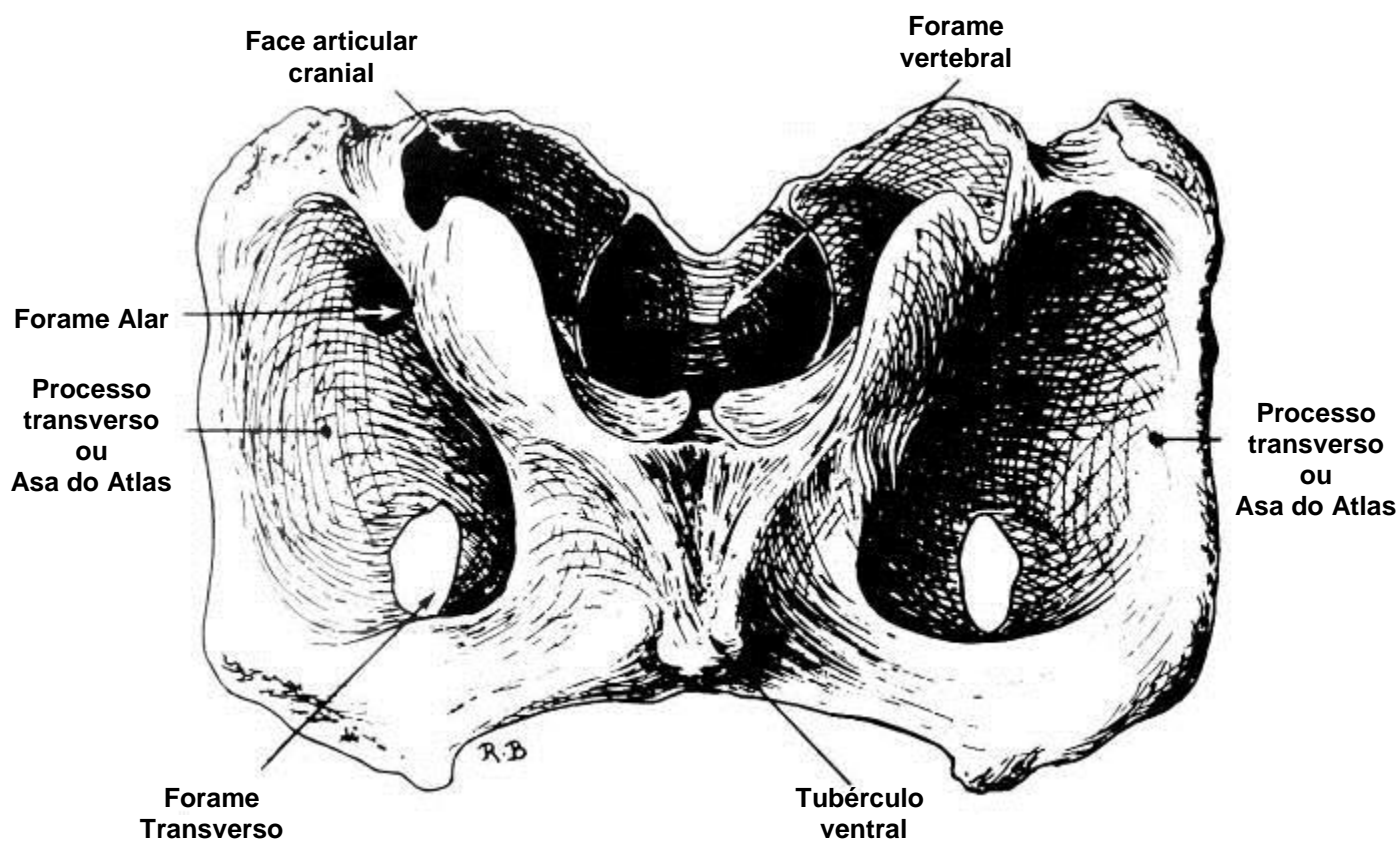
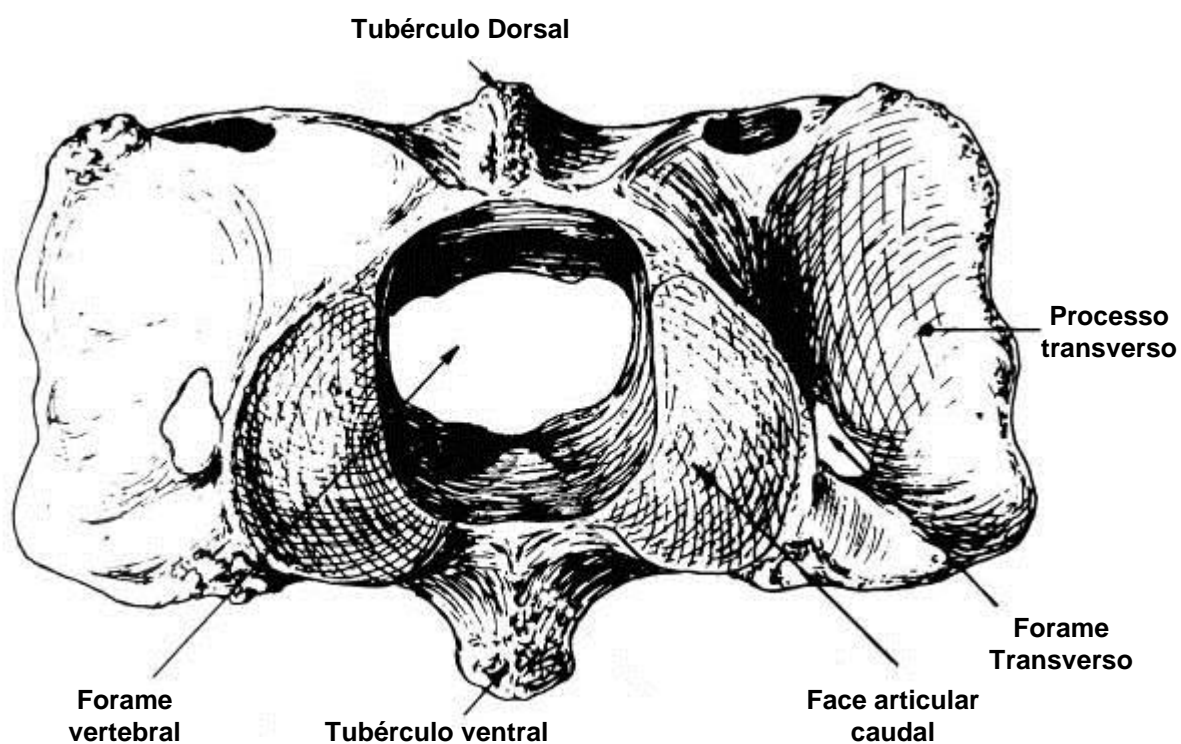


**Vista
Lateral**

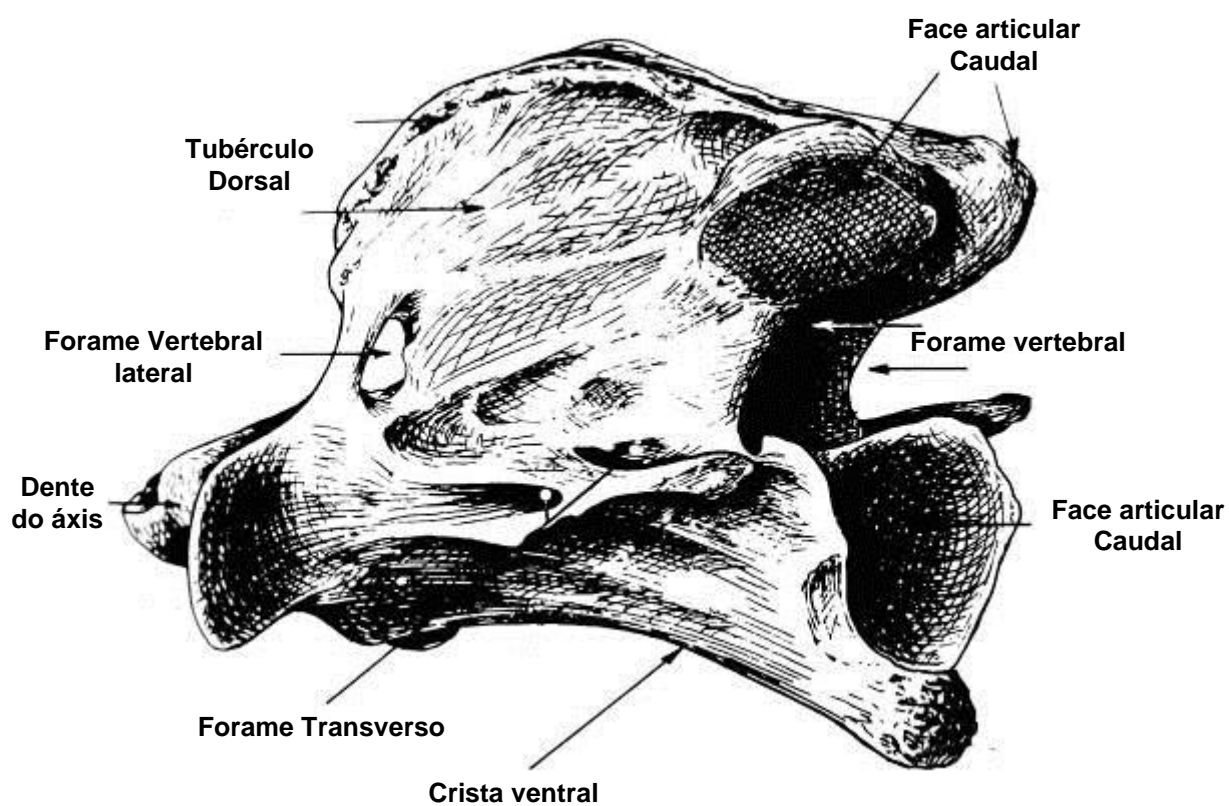
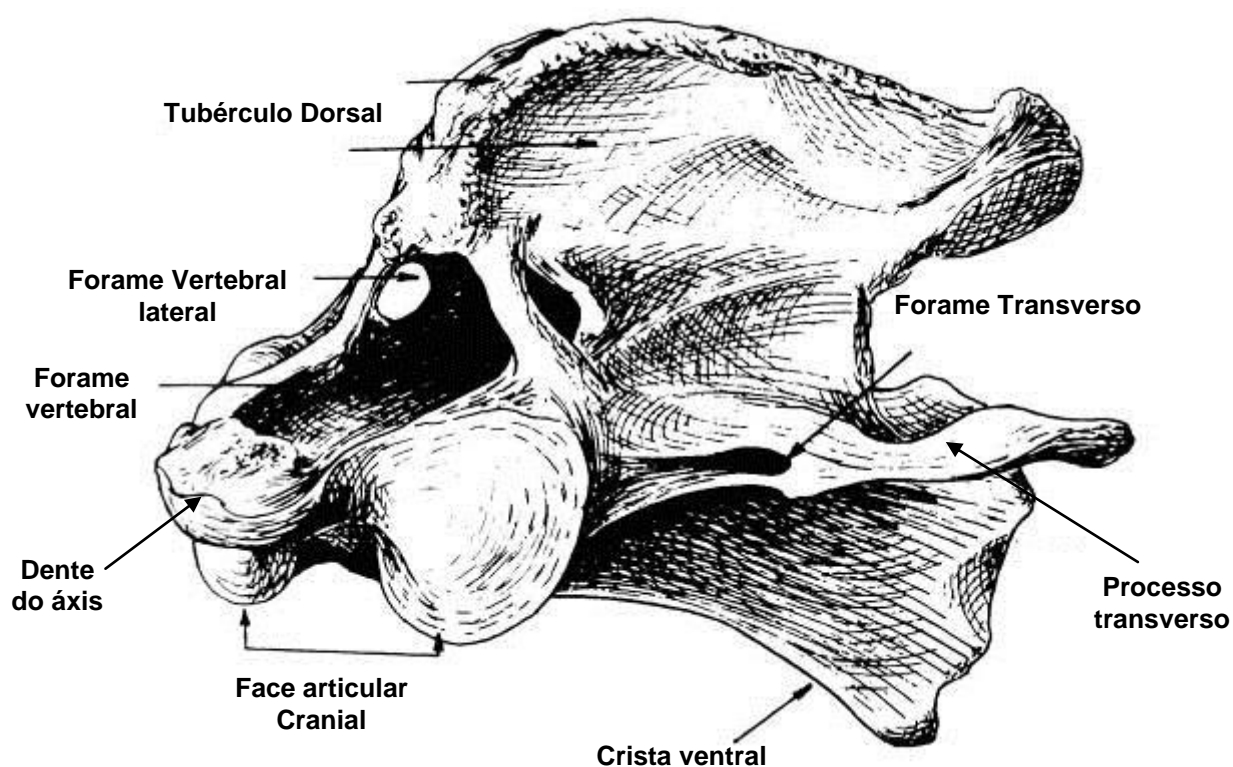
Atlas -1ª vértebra cervical



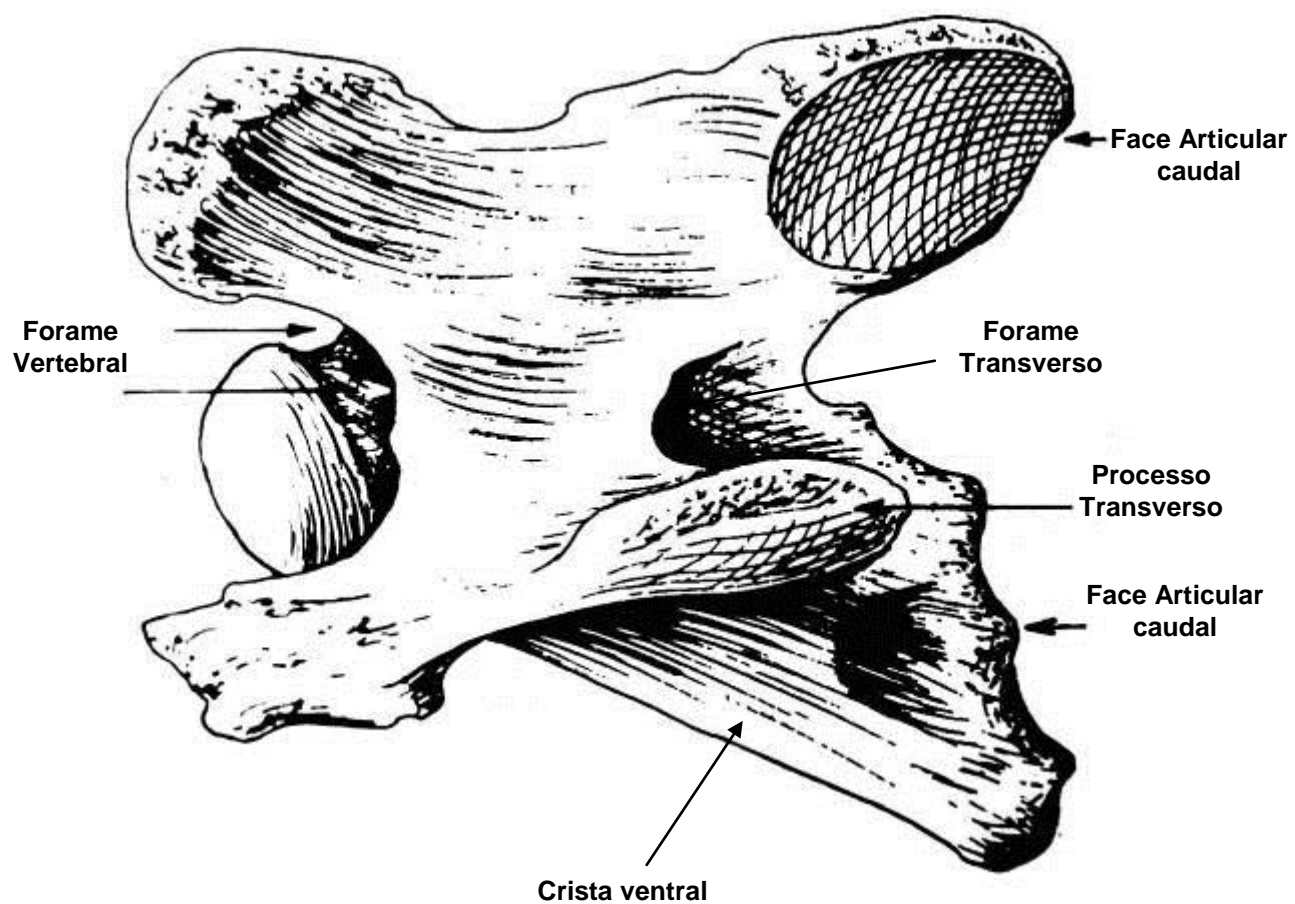
ATLAS -1ª VÉRTEBRA CERVICAL

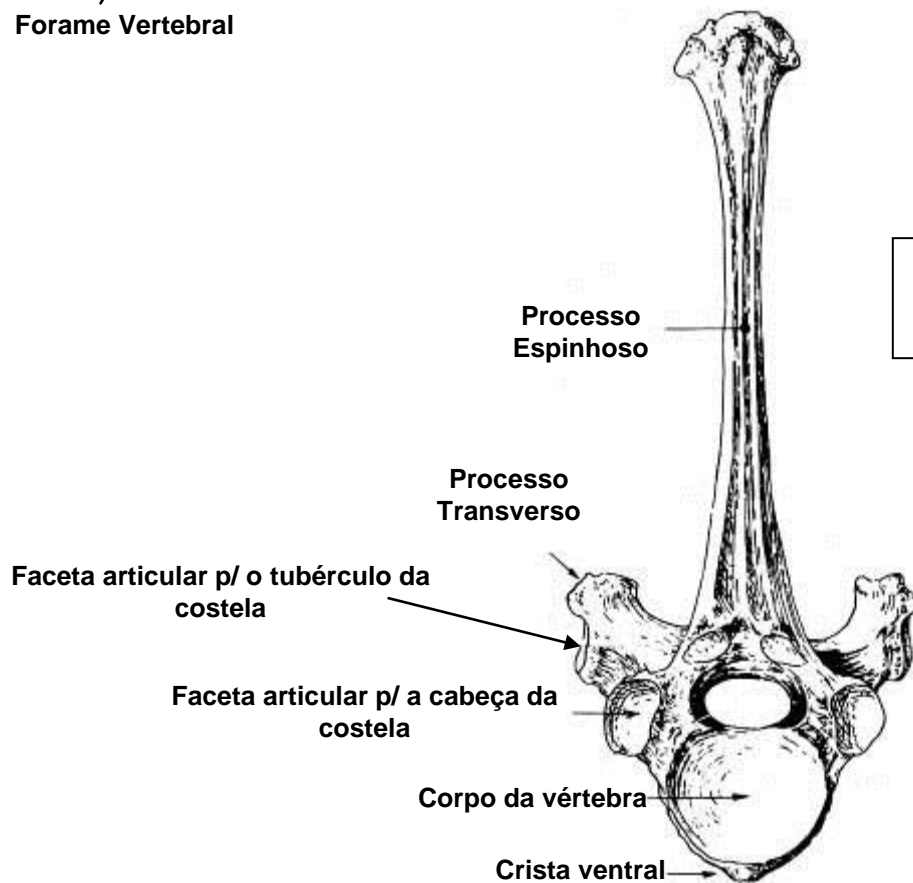
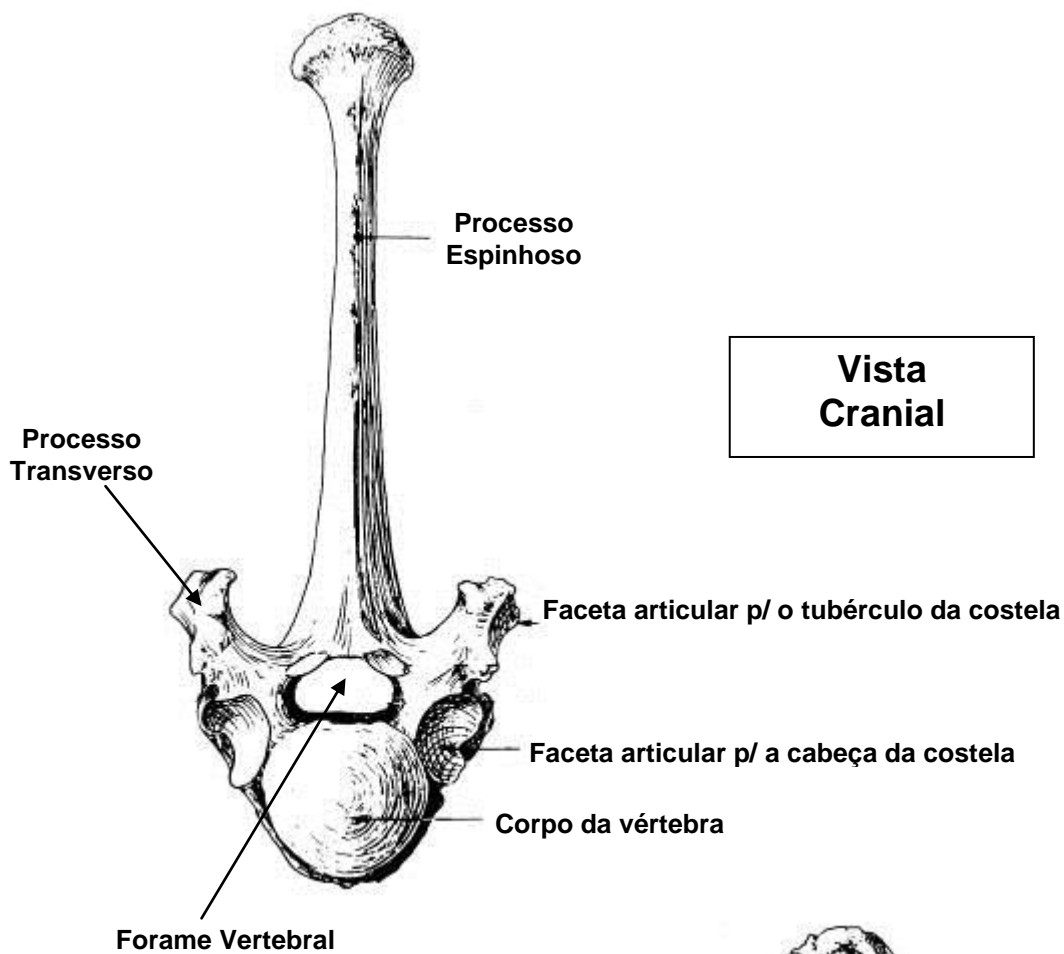


AXIS -2ª VÉRTEBRA CERVICAL

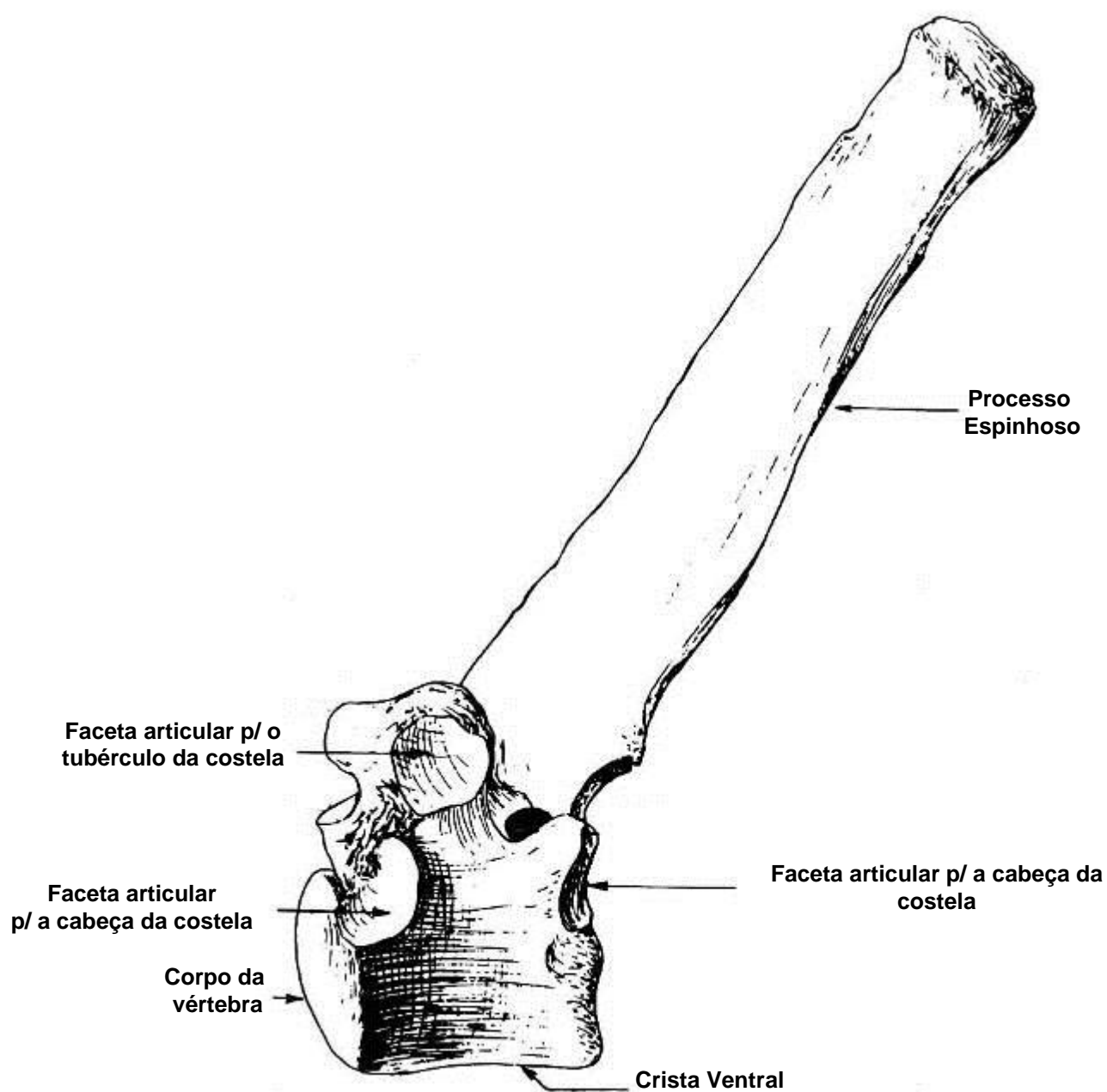


3ª A 7ª VÉRTEBRA CERVICAL





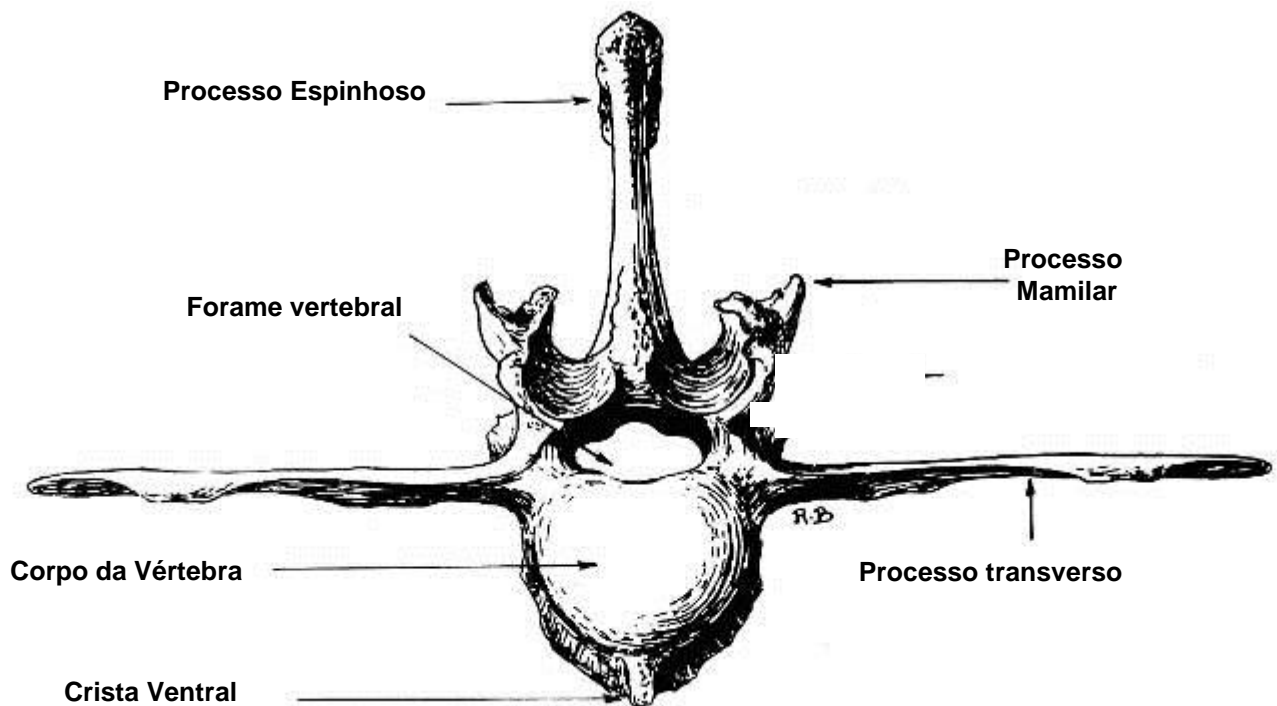
Vértebra torácica



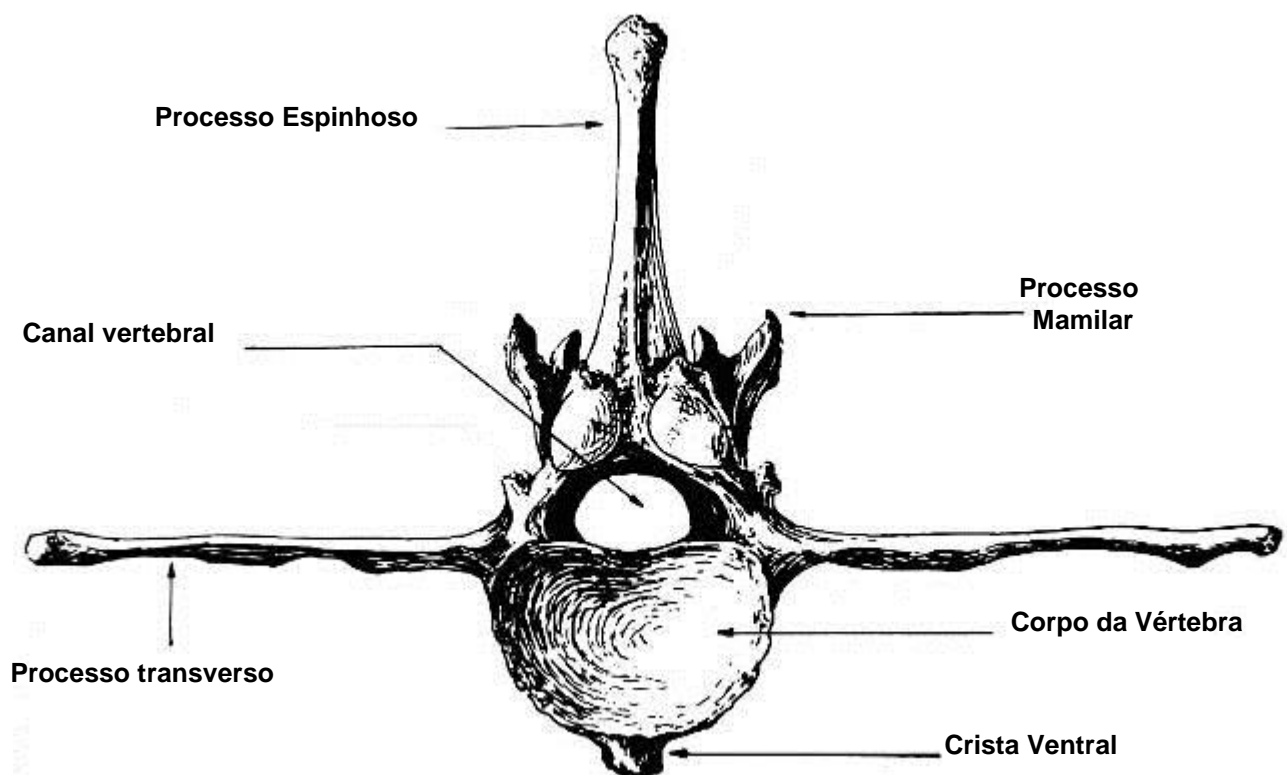
**Vista
Lateral**

Vértebra Lombar

-38-

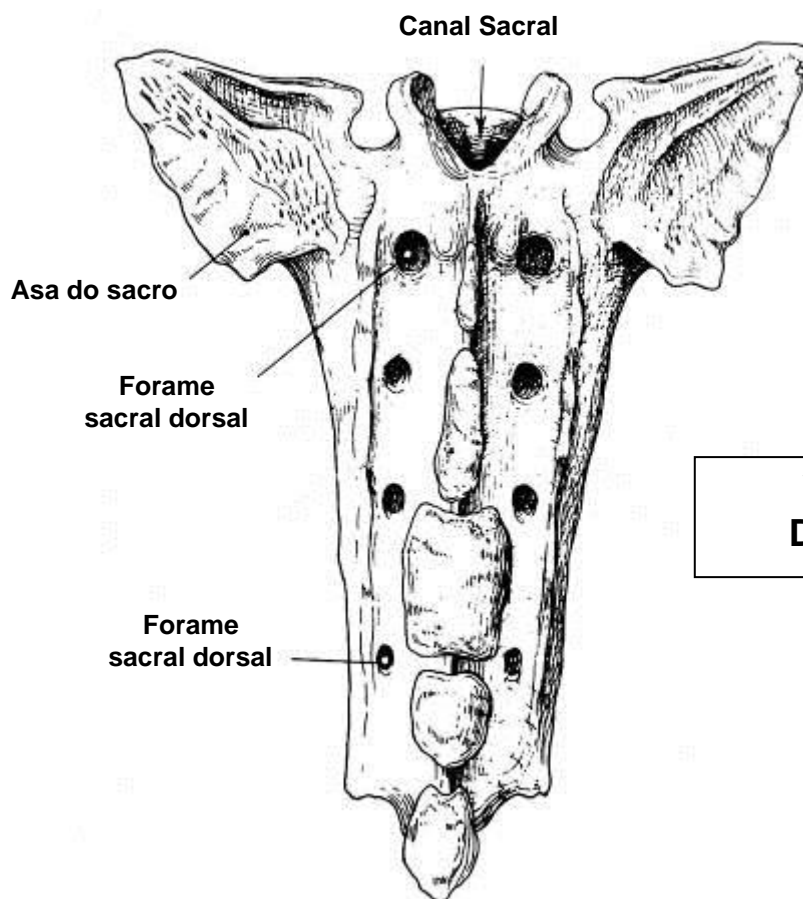


Vista Cranial

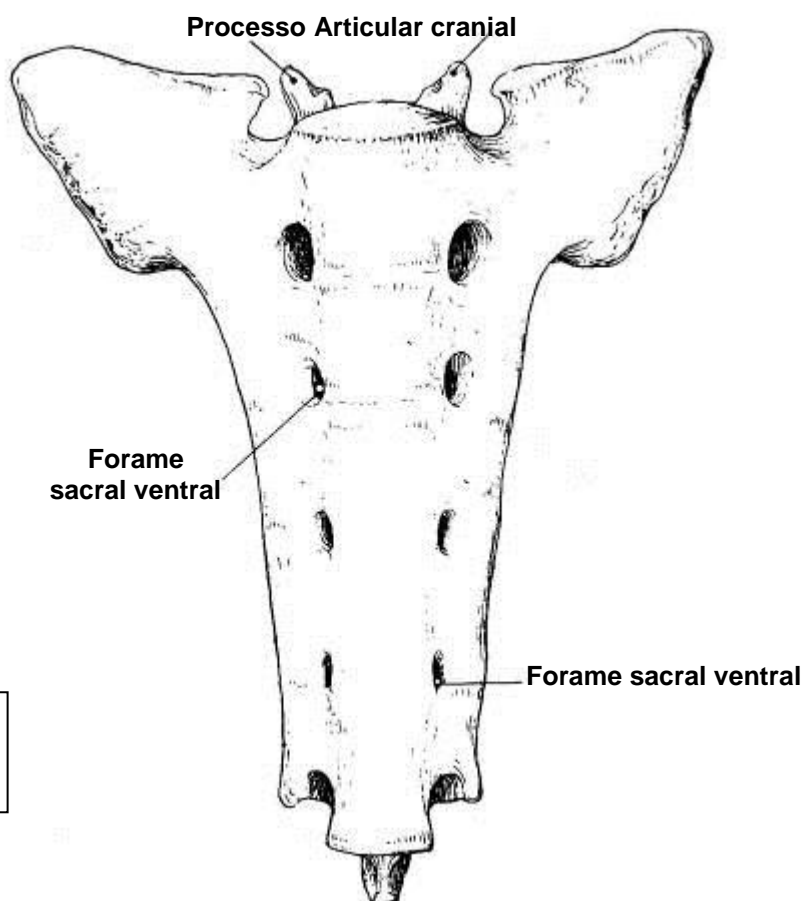


Vista Caudal

OSSO SACRO

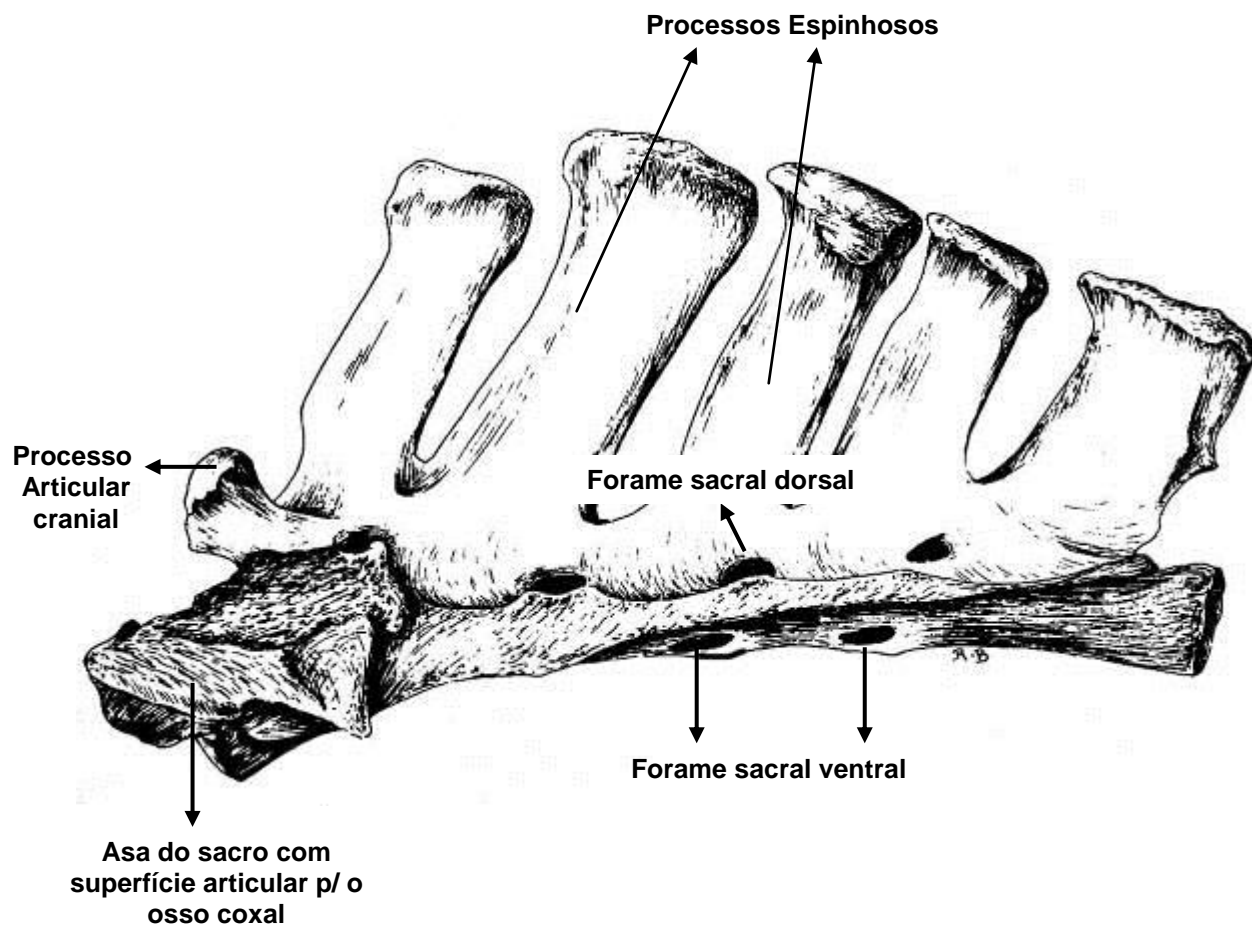


**Vista
Dorsal**



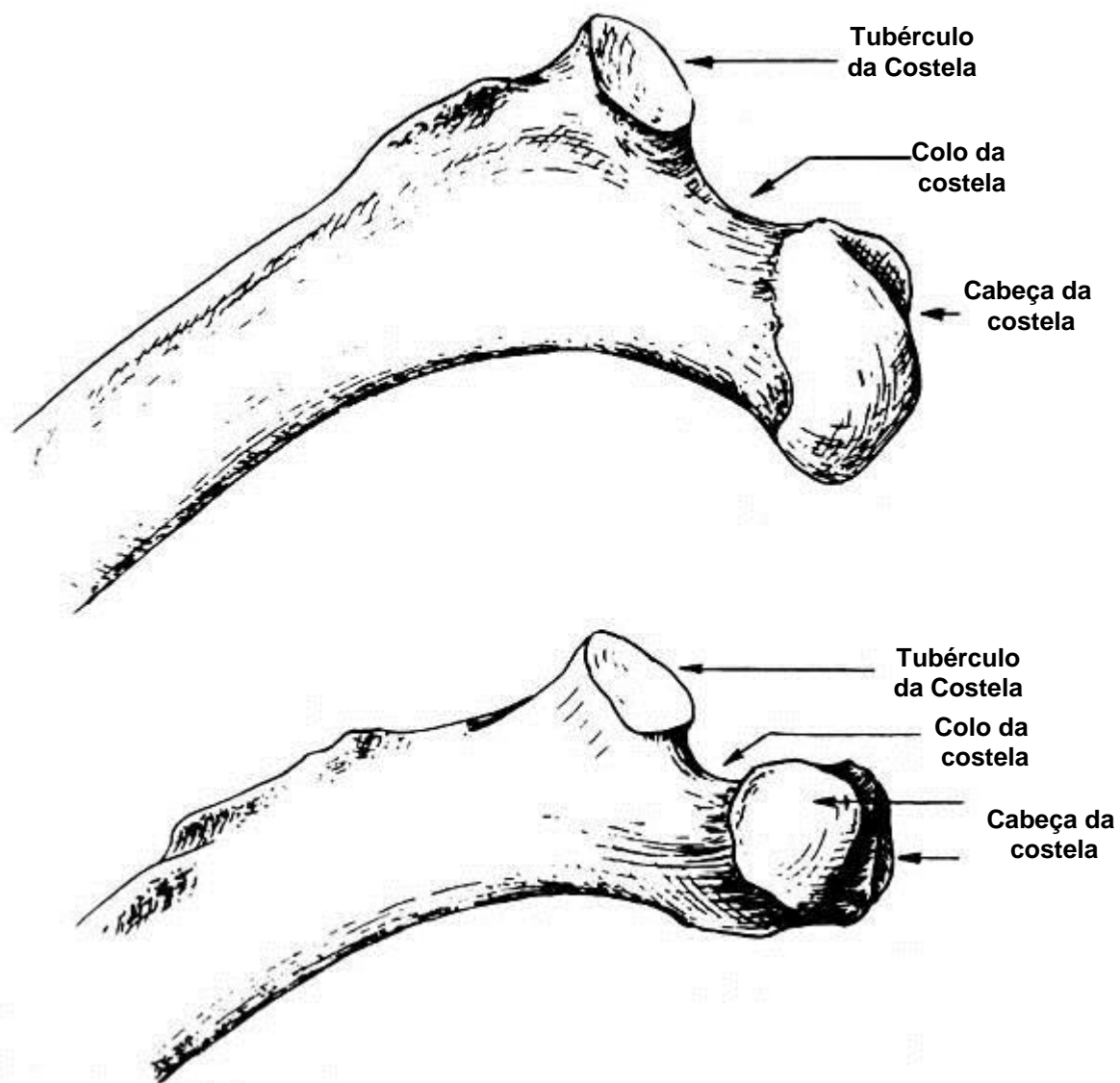
**Vista
Ventral**

OSSO SACRO

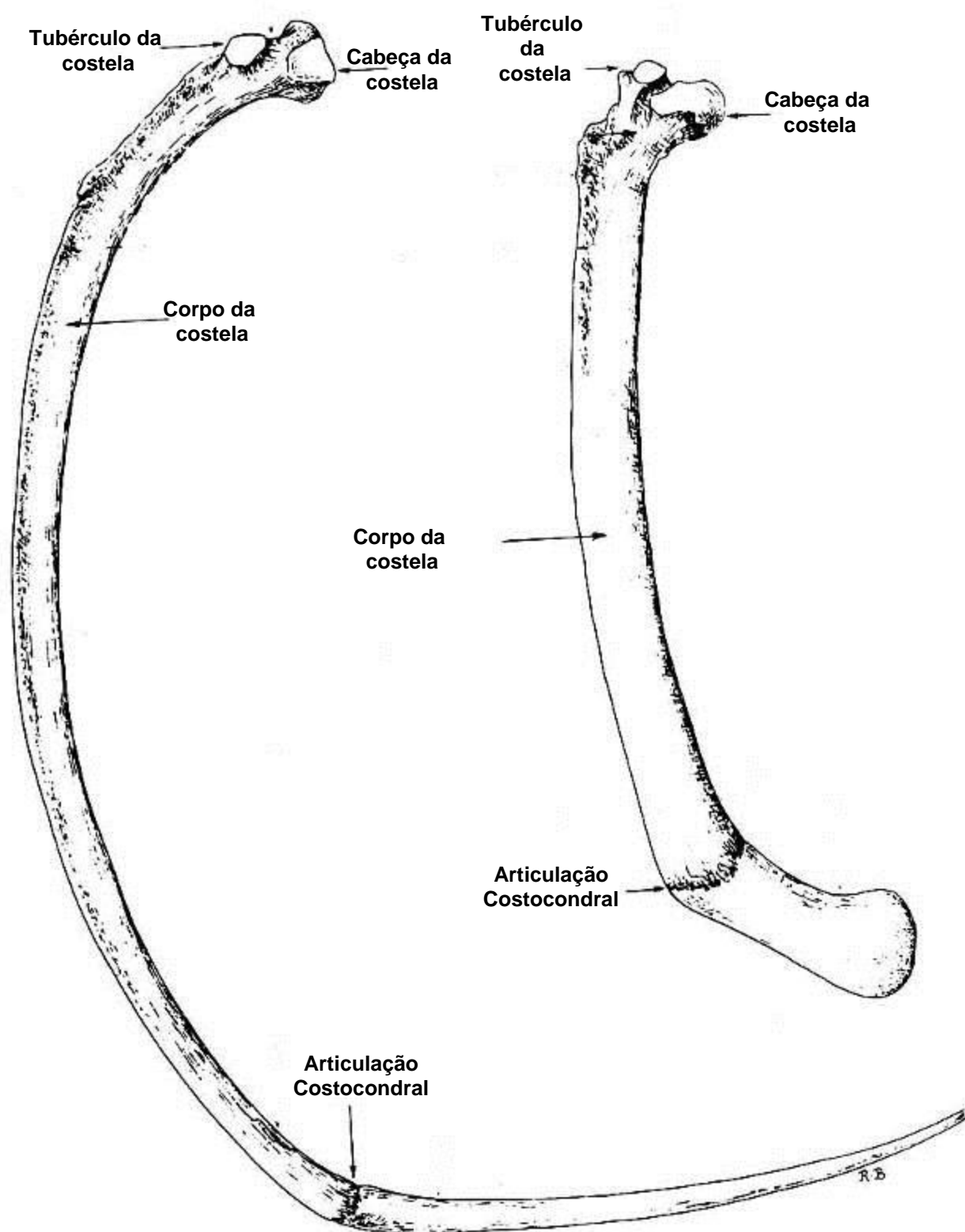


**Vista
Lateral**

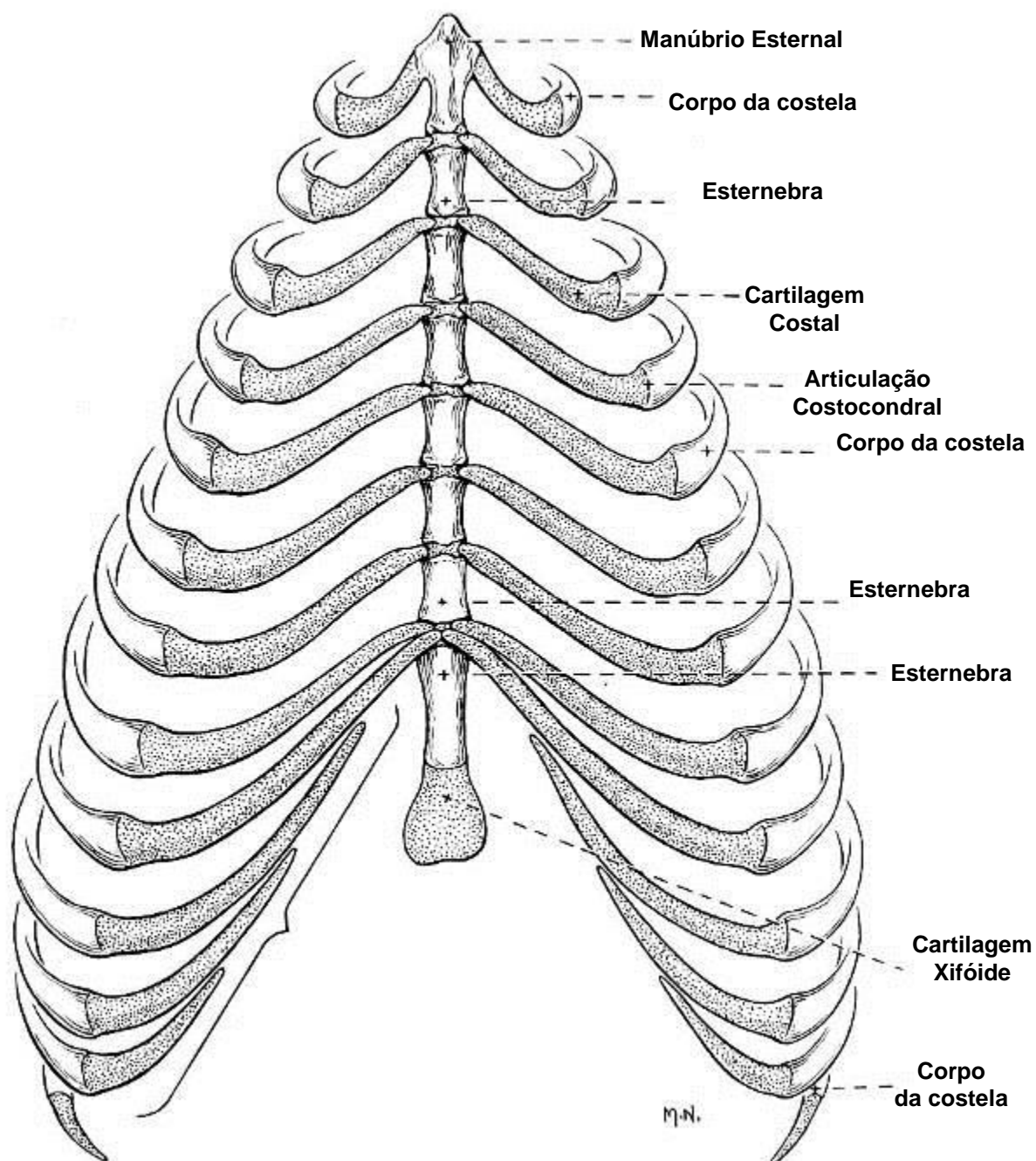
COSTELAS



COSTELAS



ESTERNO DO CÃO

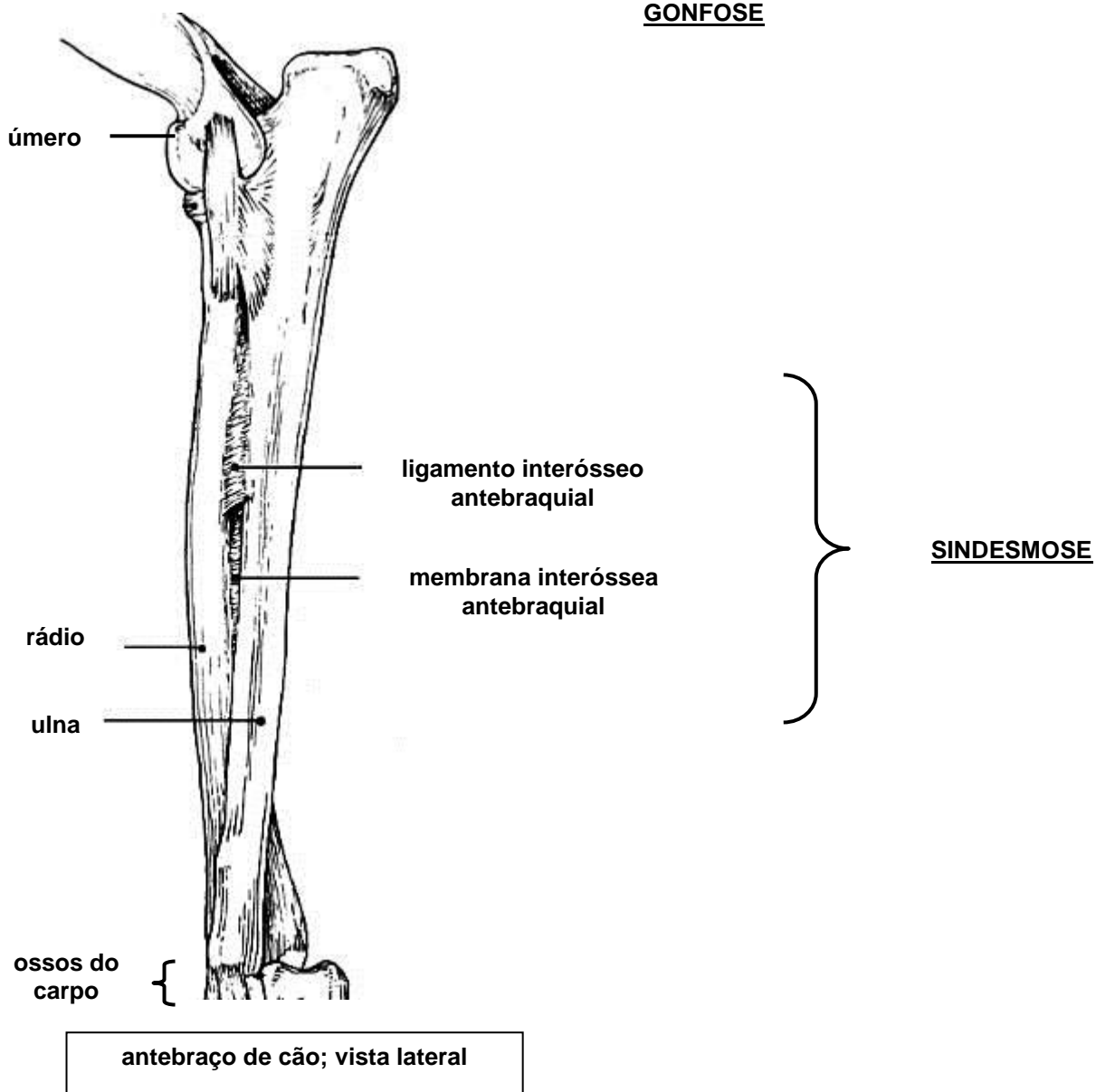
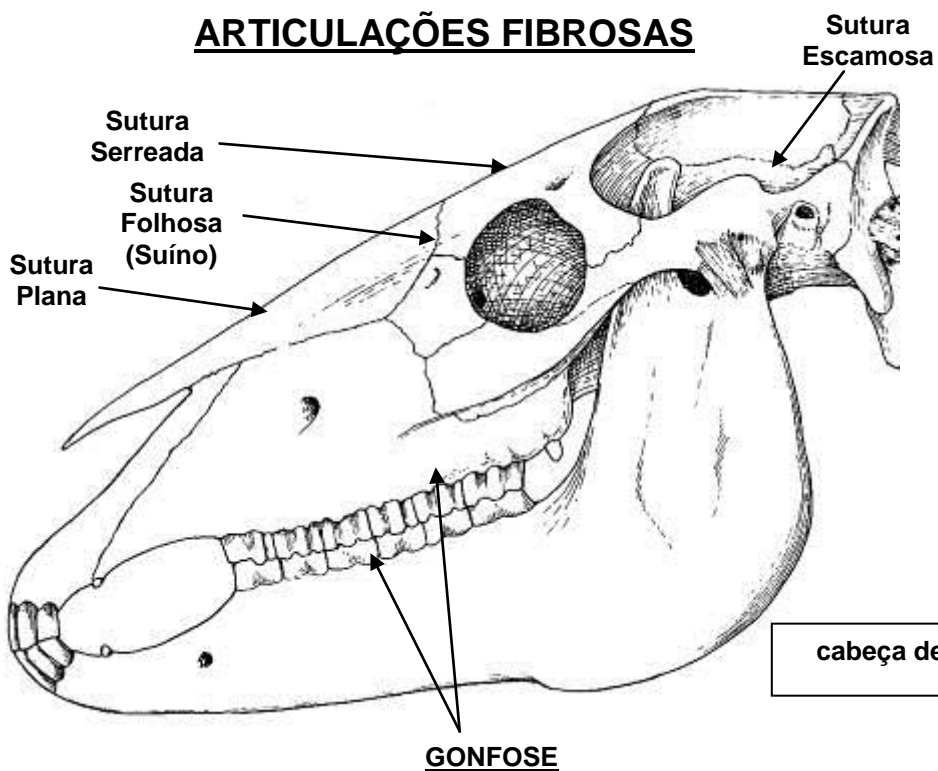


**Vista
Ventral**

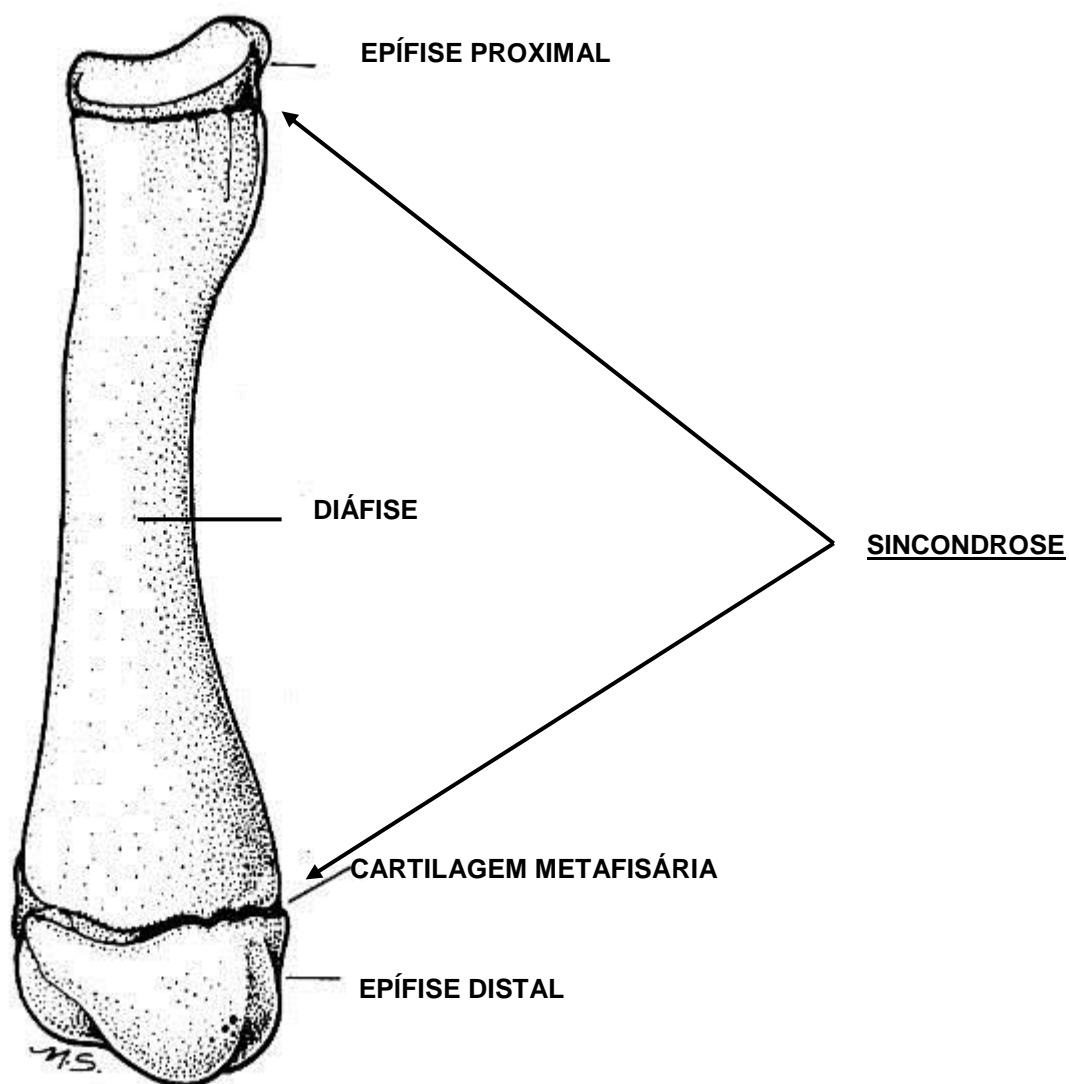
APARELHO LOCOMOTOR

ARTROLOGIA

ARTICULAÇÕES FIBROSAS

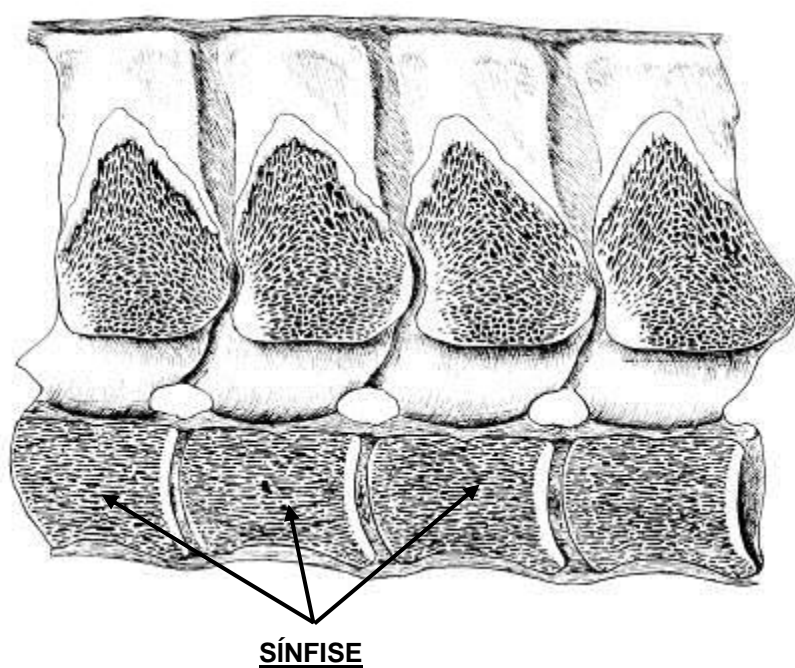


ARTICULAÇÕES CARTILAGÍNEAS



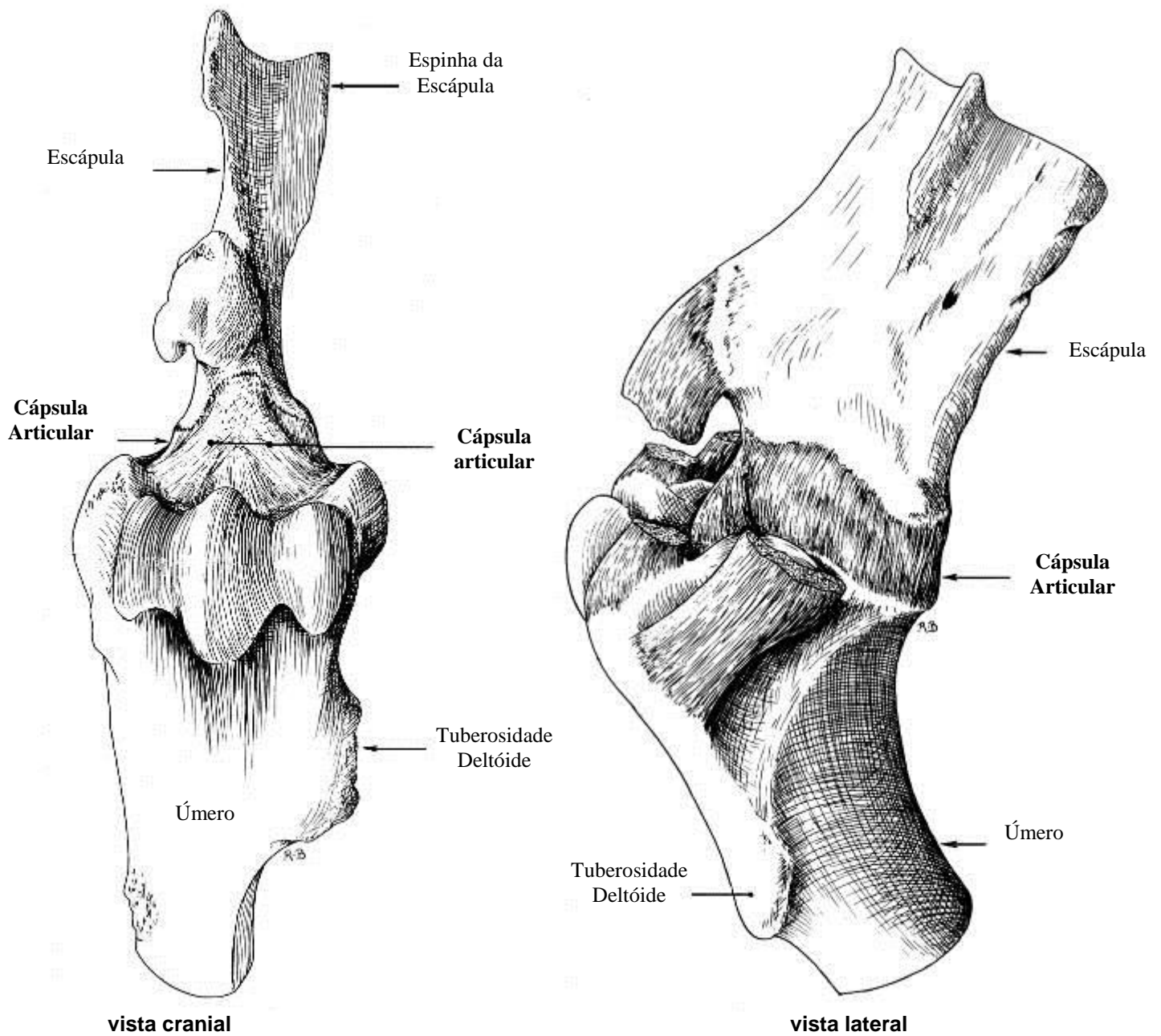
osso rádio de cão jovem

vista medial de secção
mediana das vértebras



ARTICULAÇÕES SINOVIAIS

ARTICULAÇÃO ESCÁPULO- UMERAL

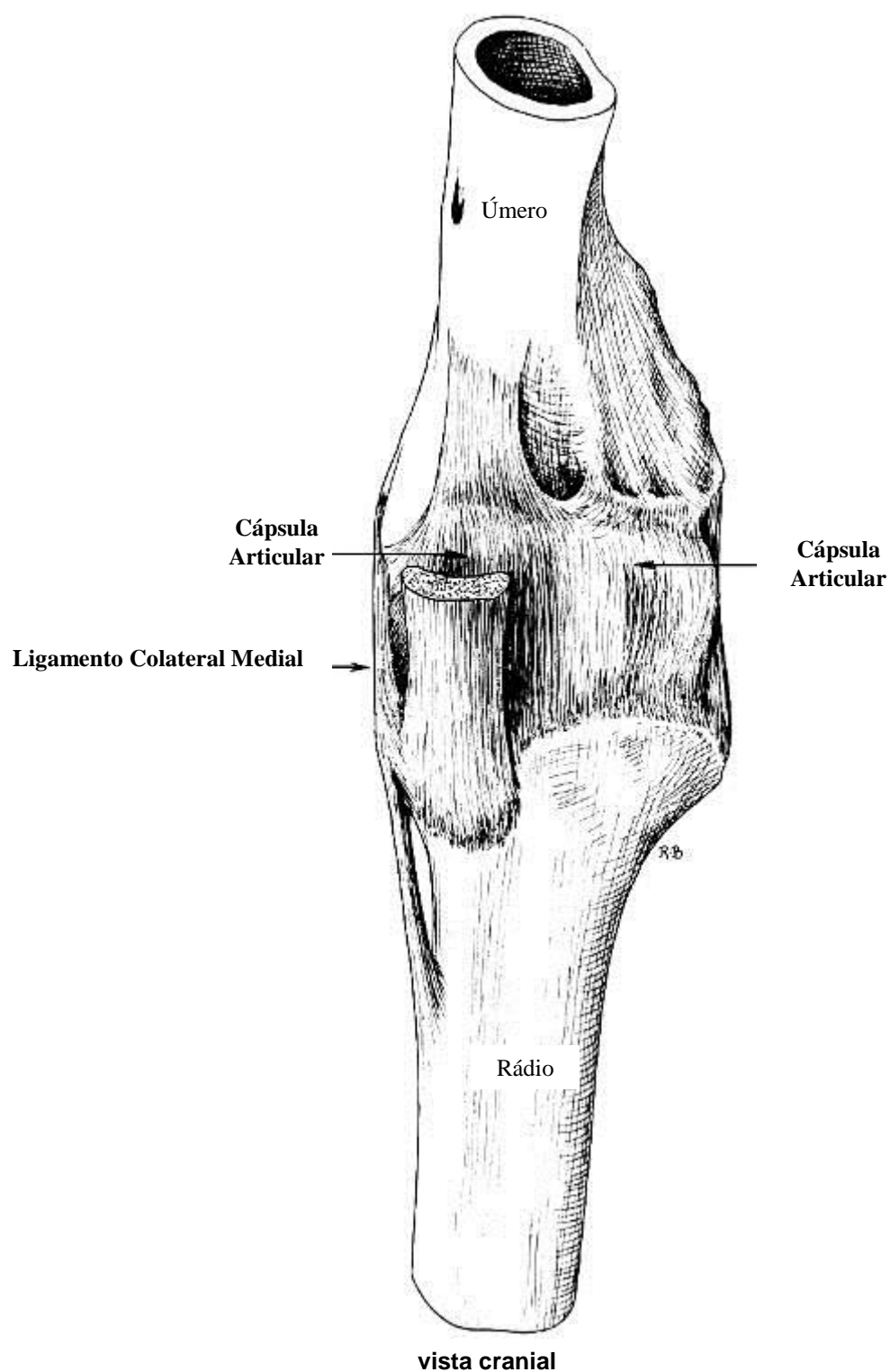


Classificação: esferóide

Movimentos: extensão, flexão, adução, abdução e circundação (primatas)

ARTICULAÇÕES SINOVIAIS

ARTICULAÇÃO ÚMERO-RÁDIO-ULNAR ou ARTICULAÇÃO CÚBITA

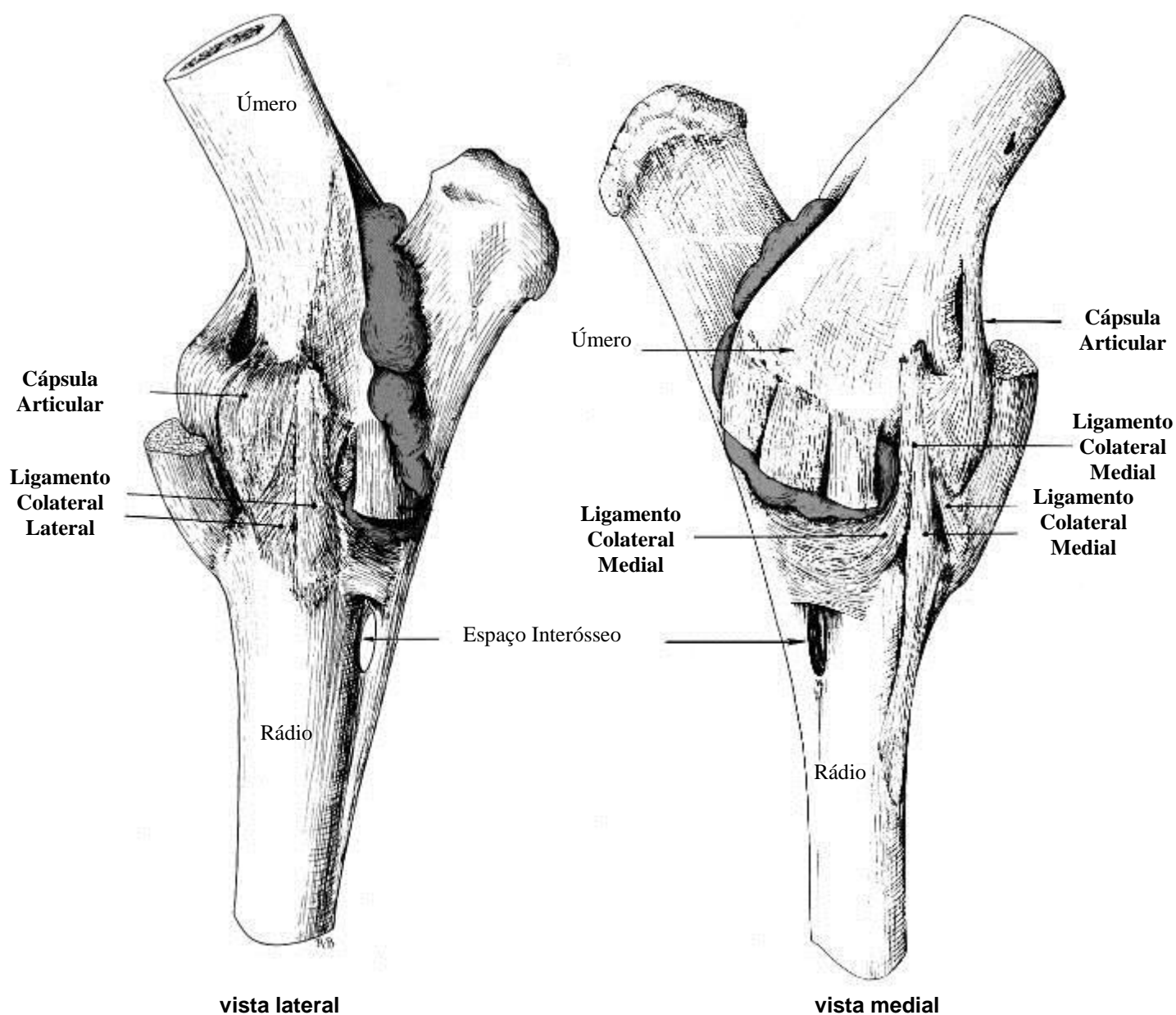


Classificação: gínglimo angular perfeito

Movimentos: extensão e flexão

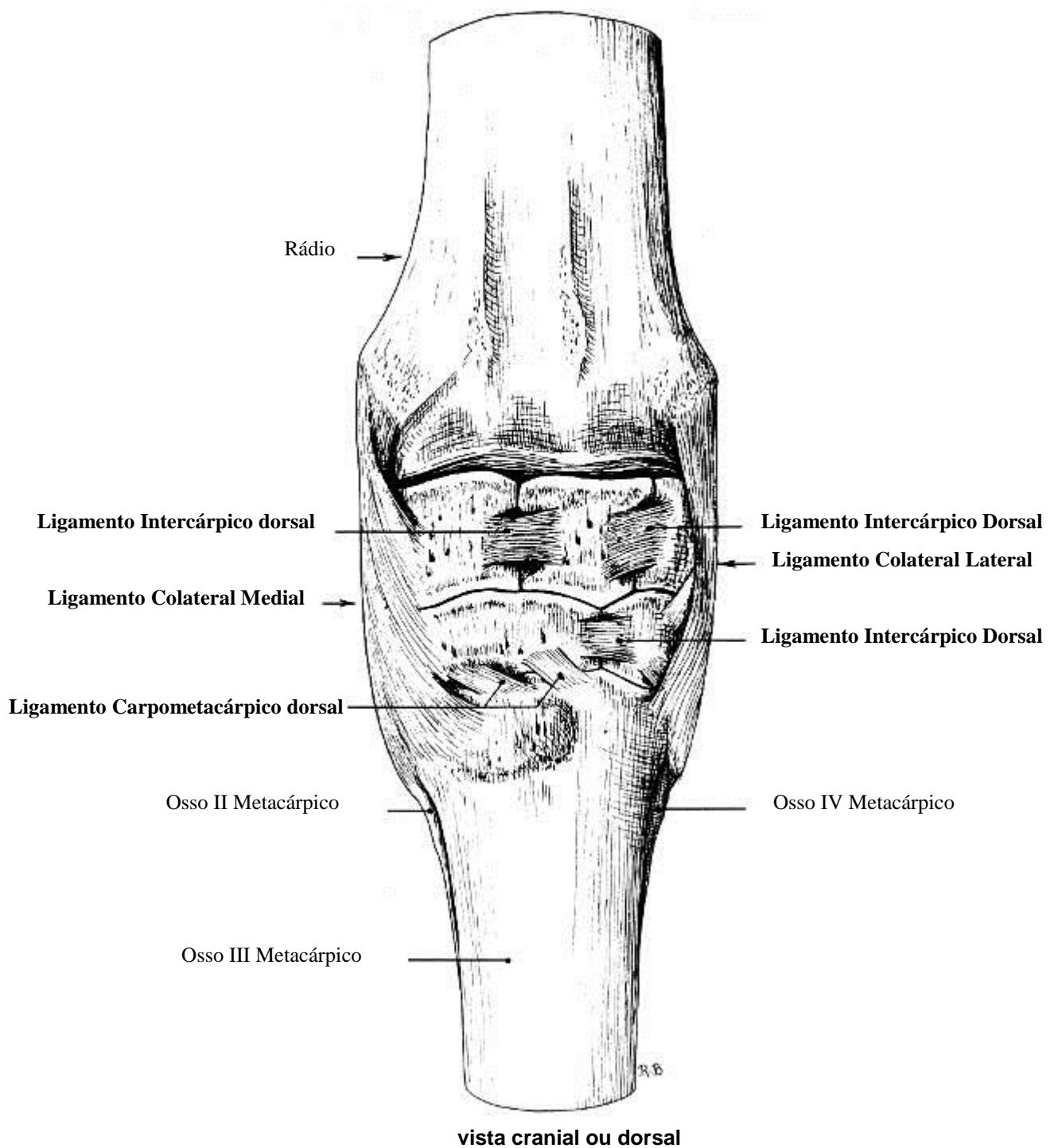
ARTICULAÇÕES SINOVIAIS

ARTICULAÇÃO ÚMERO-RÁDIO-ULNAR ou ARTICULAÇÃO CÚBITA



ARTICULAÇÕES SINOVIAIS

ARTICULAÇÃO CÁRPICA

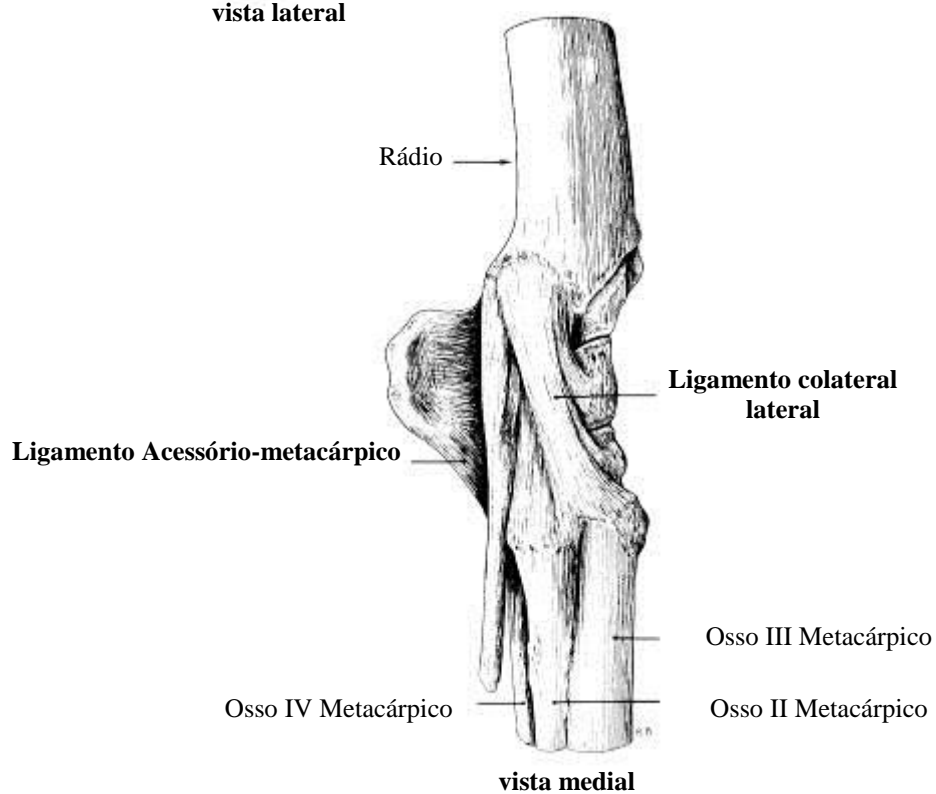
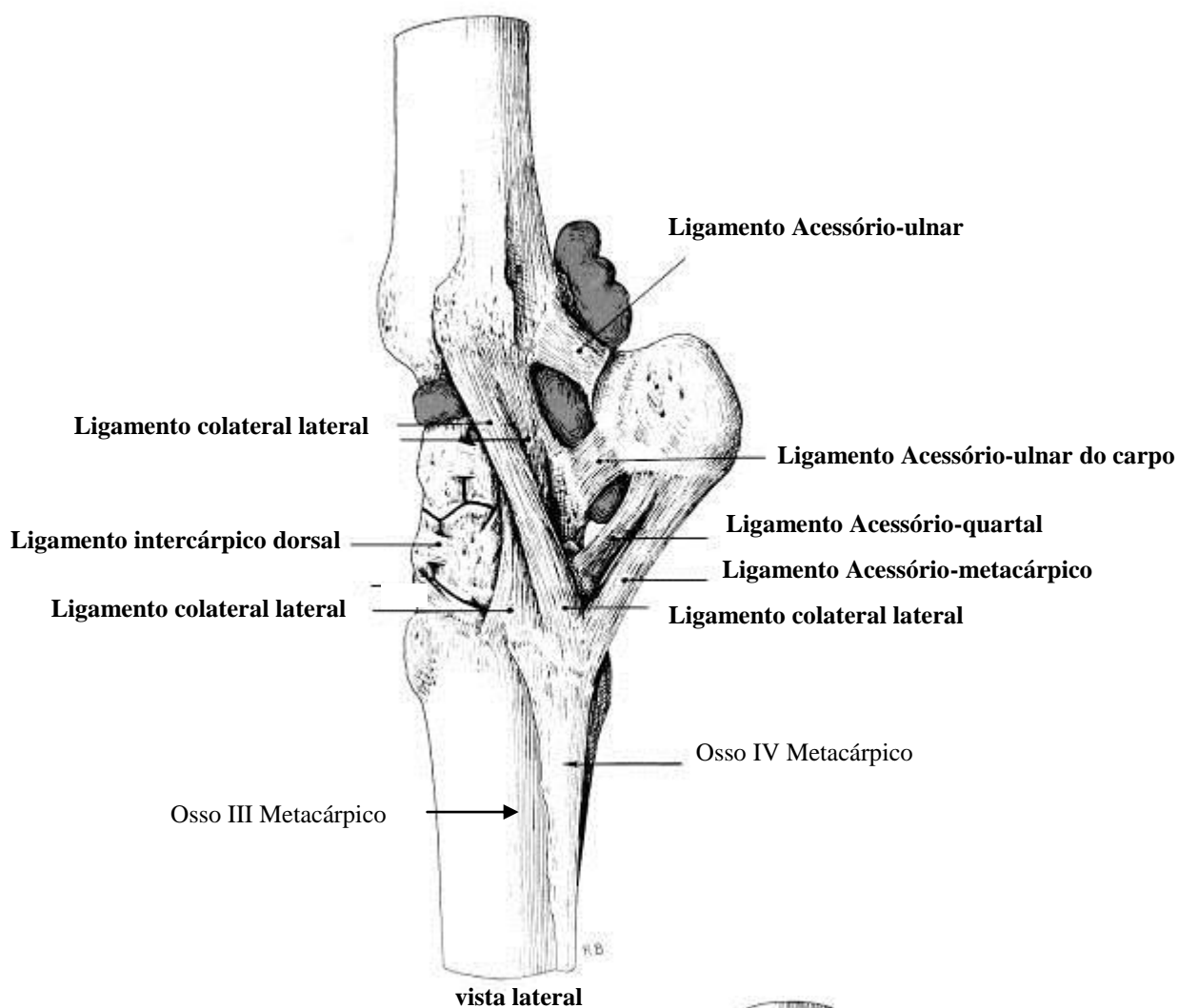


Classificação: elipsóide

Movimentos: extensão, flexão, adução, abdução e circundação (primatas e ursídeos)

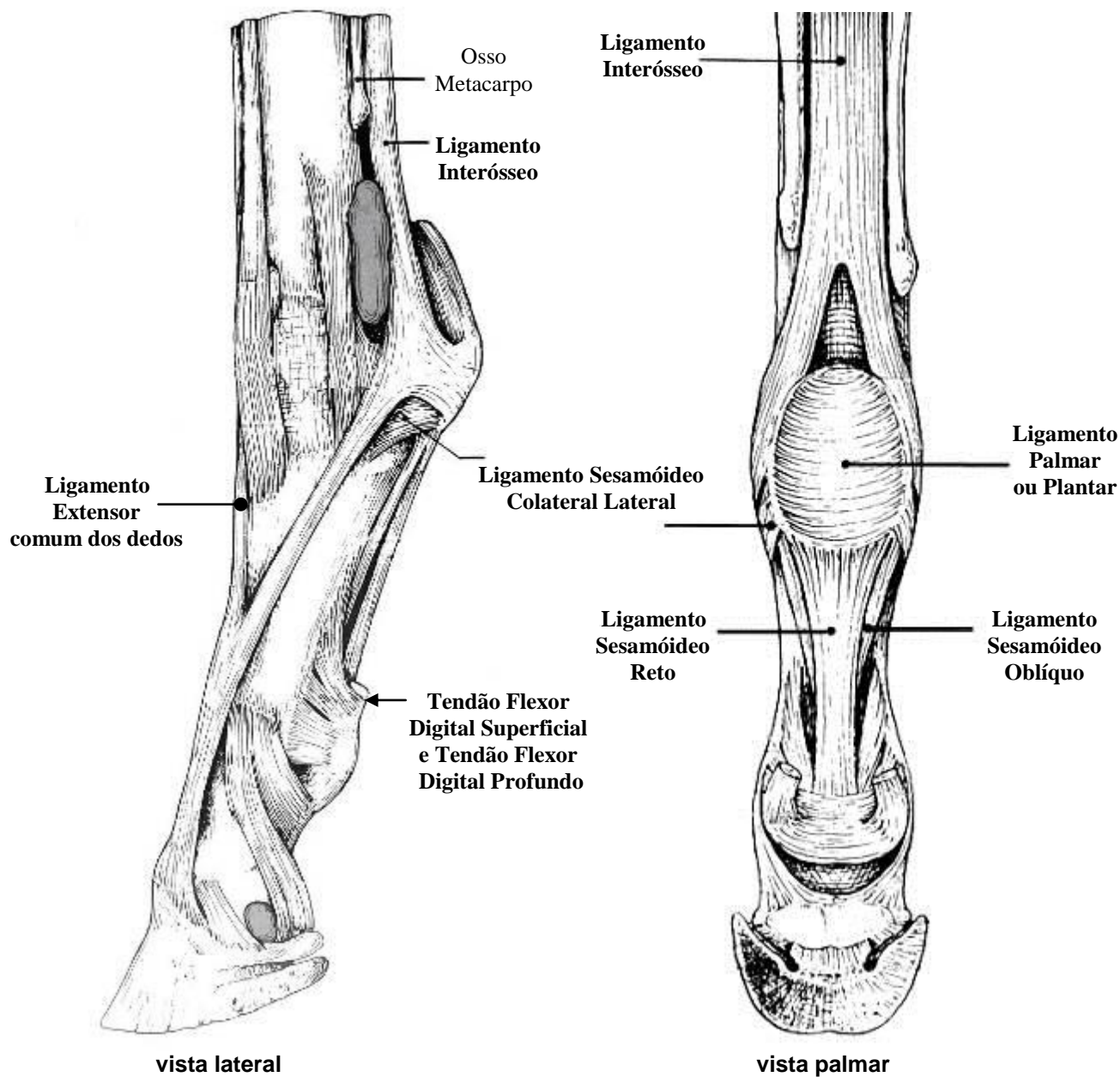
ARTICULAÇÕES SINOVIAIS

ARTICULAÇÃO CÁRPICA



ARTICULAÇÕES SINOVIAIS

ARTICULAÇÃO METACARPOFALANGEANA ou METATARSOFALENGEANA

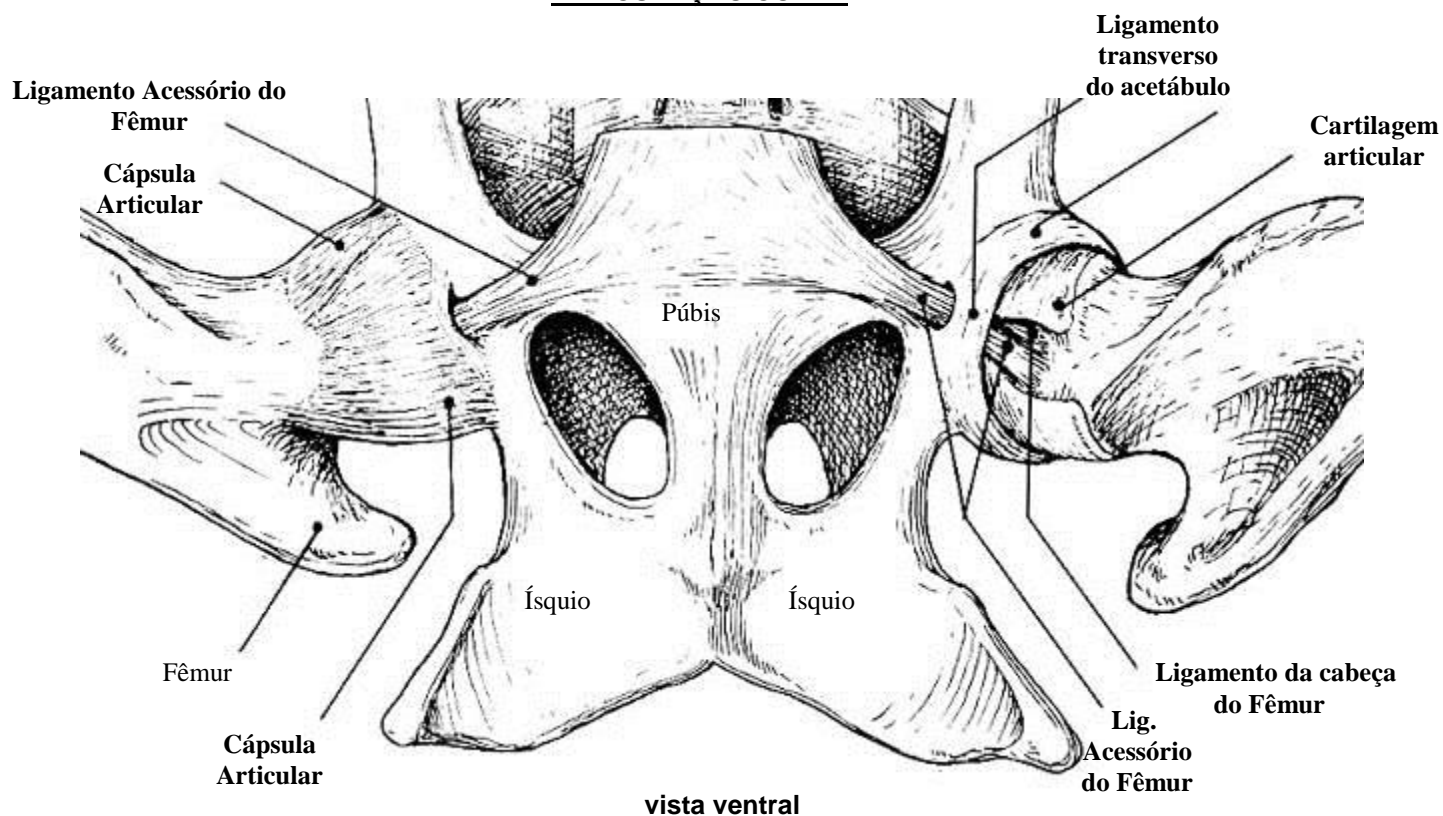


Classificação: gínglimo

Movimentos: extensão, flexão, adução, abdução

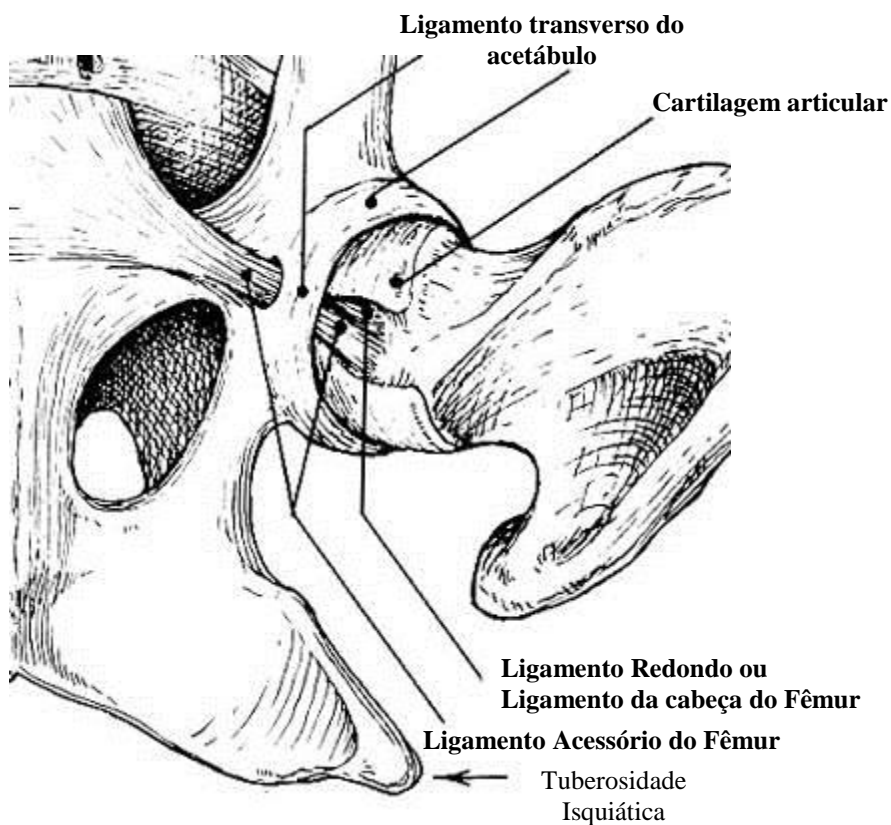
ARTICULAÇÕES SINOVIAIS

ARTICULAÇÃO COXAL



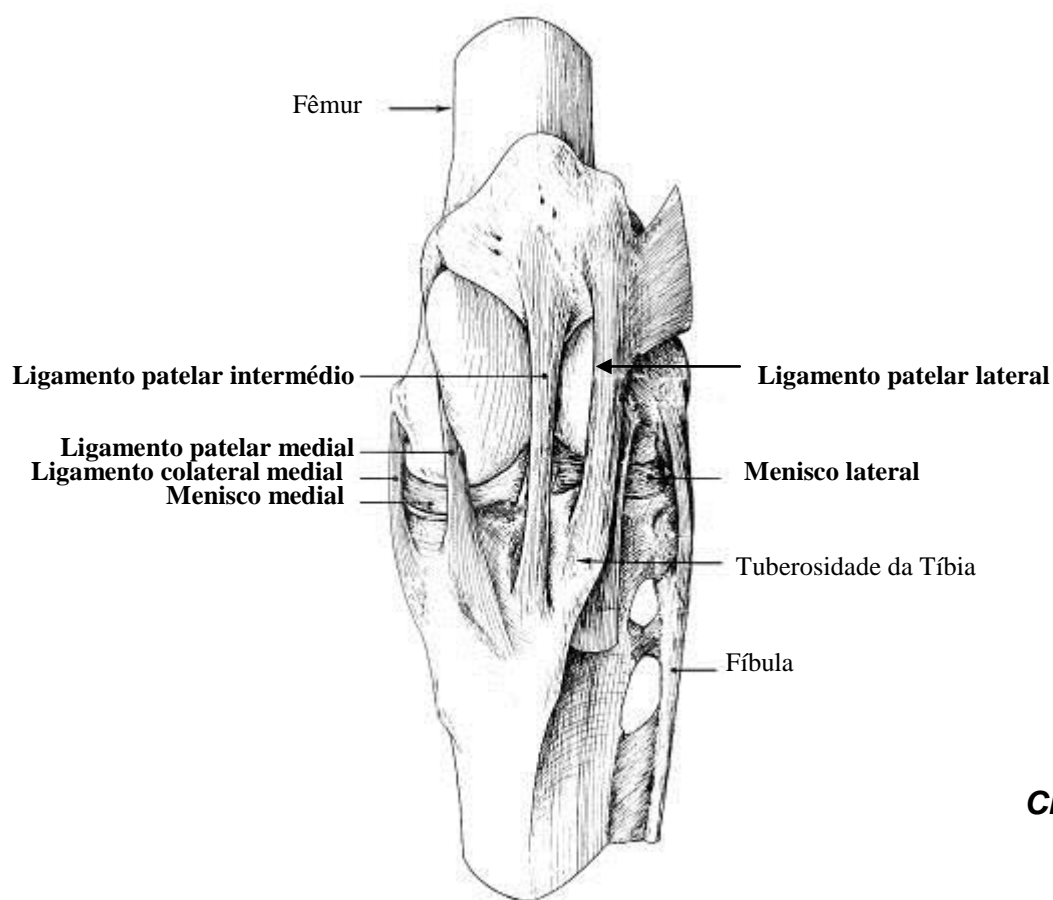
Classificação:
Cotílica

Movimentos:
extensão,
flexão,
abdução,
adução e
circundação



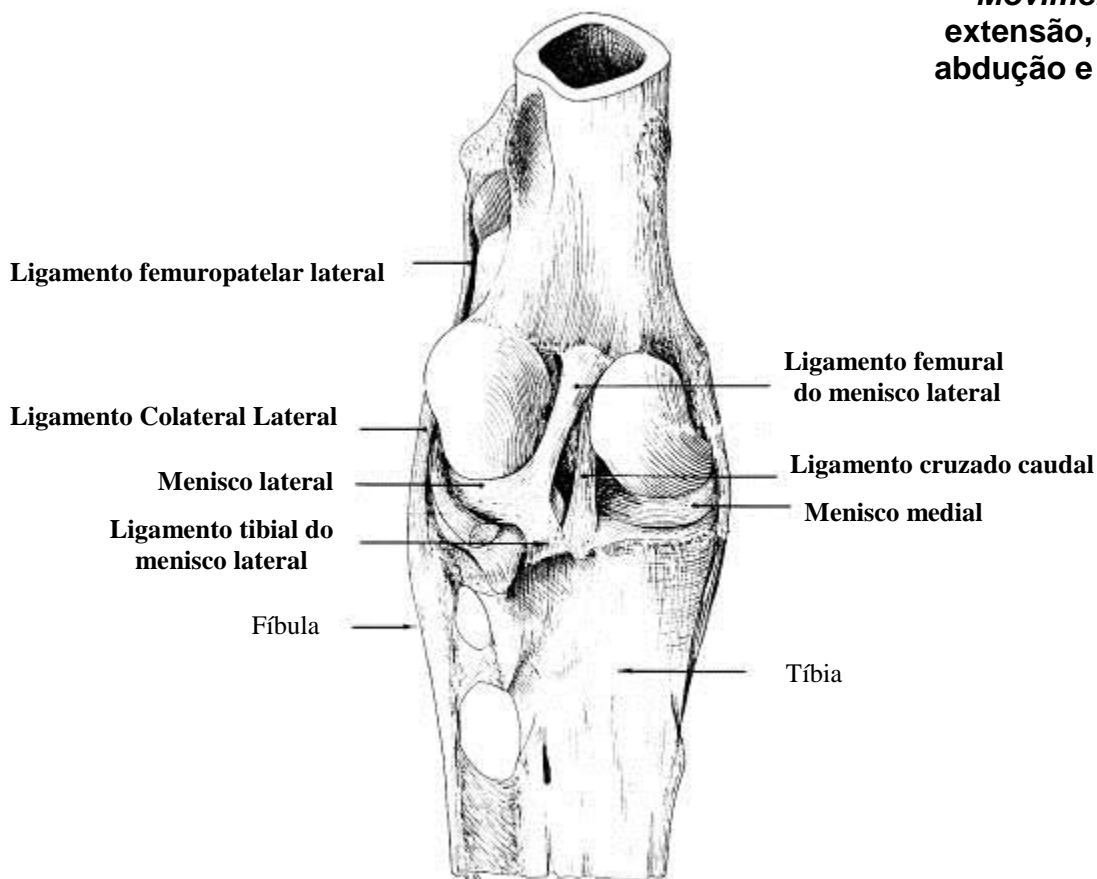
ARTICULAÇÕES SINOVIAIS

ARTICULAÇÃO FÊMURO-TIBIO-PATELAR



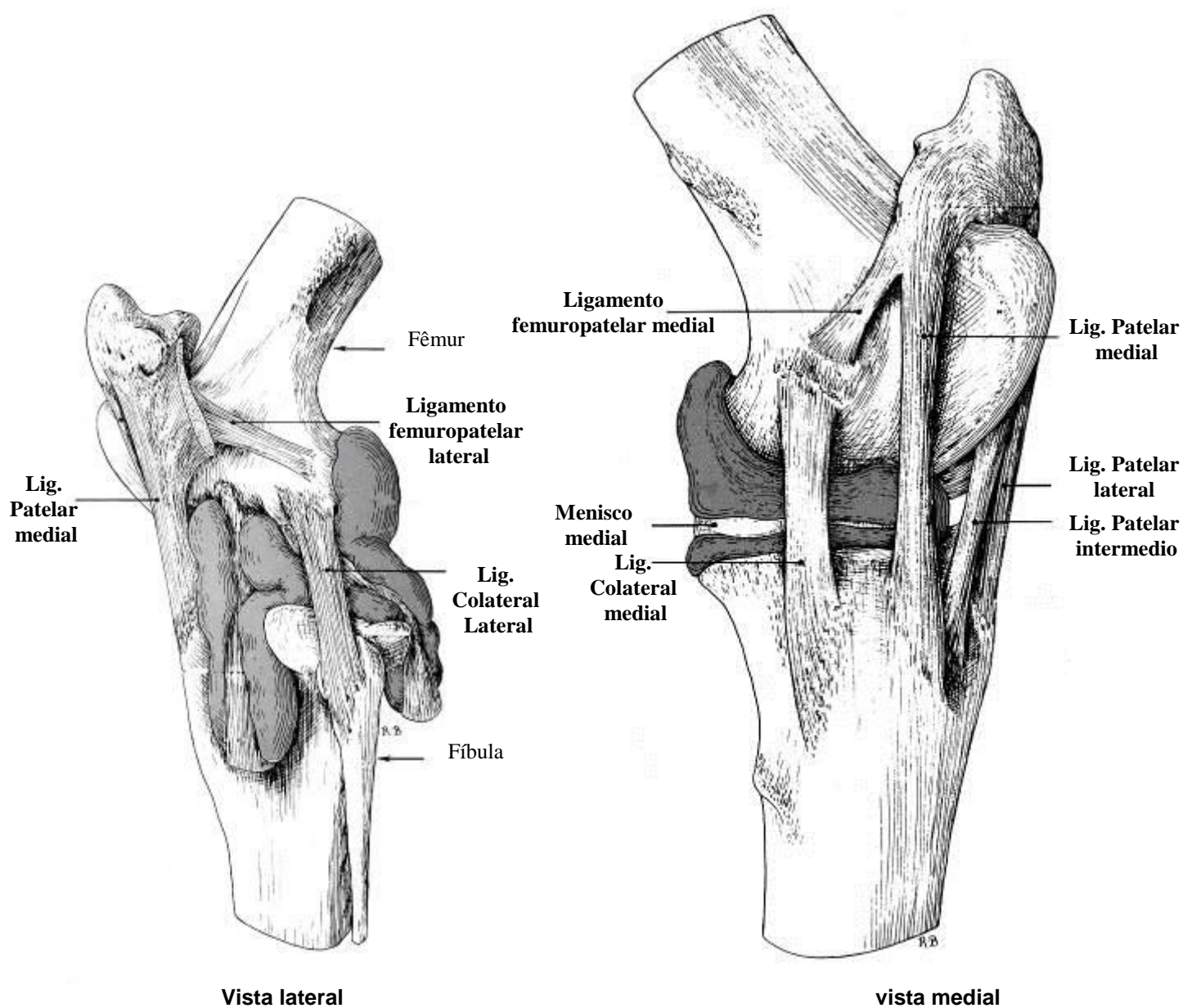
Classificação:
Condilar

Movimentos:
extensão, flexão,
abdução e adução



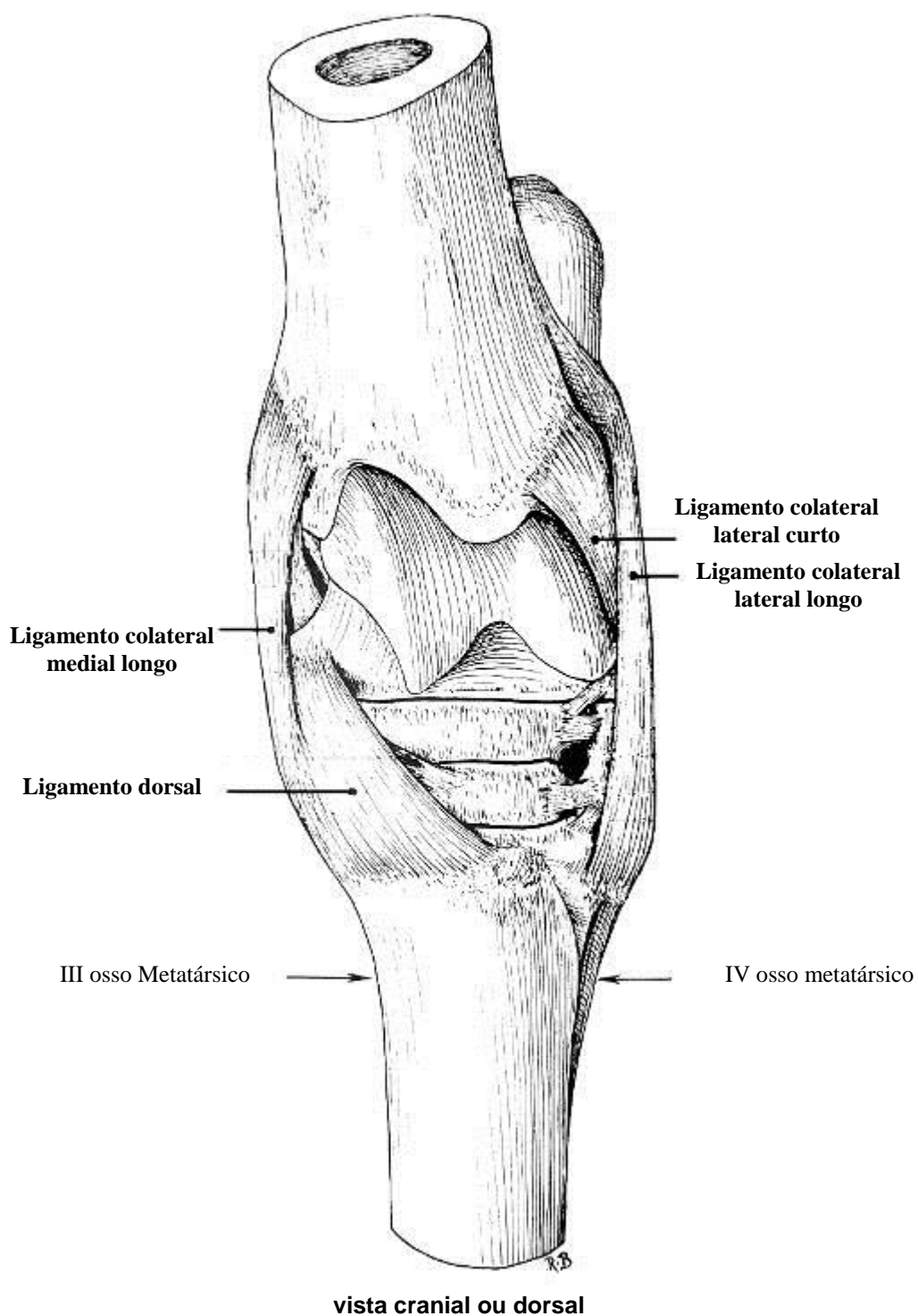
ARTICULAÇÕES SINOVIAIS

ARTICULAÇÃO FÊMURO-TIBIO-PATELAR



ARTICULAÇÕES SINOVIAIS

ARTICULAÇÃO TÁRSICA

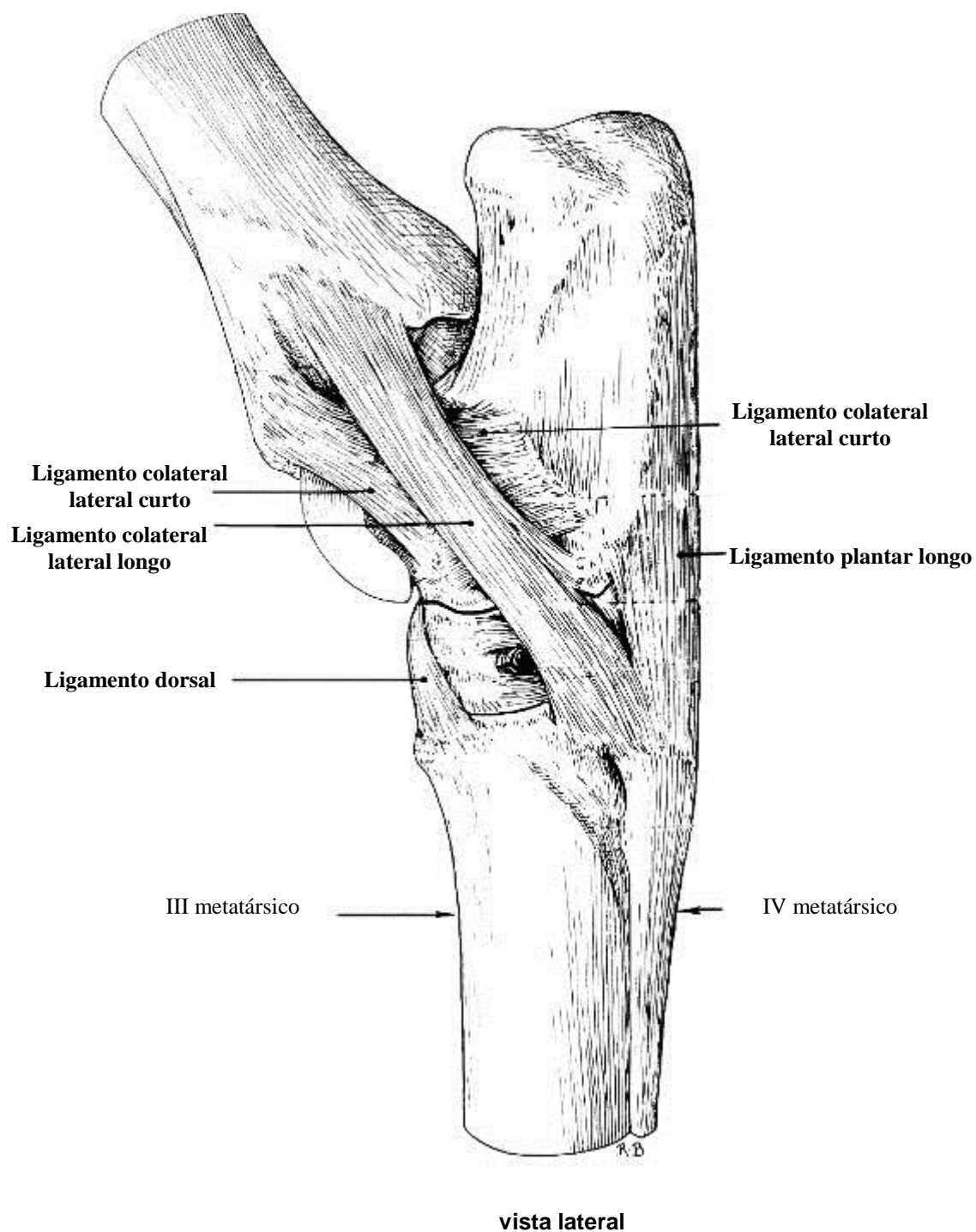


Classificação: gínglimo angular perfeito

Movimentos: extensão e flexão

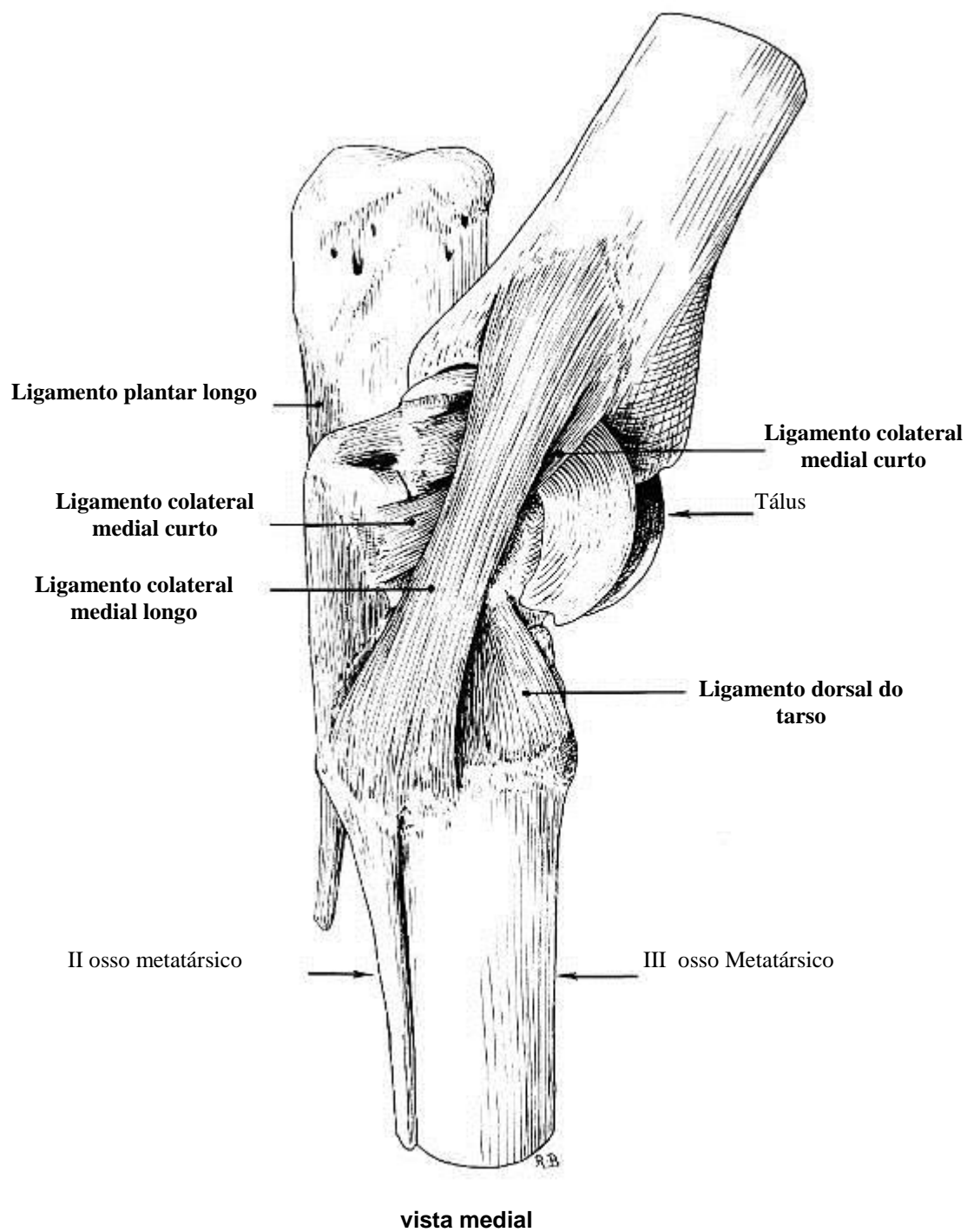
ARTICULAÇÕES SINOVIAIS

ARTICULAÇÃO TÁRSICA



ARTICULAÇÕES SINOVIAIS

ARTICULAÇÃO TÁRSICA

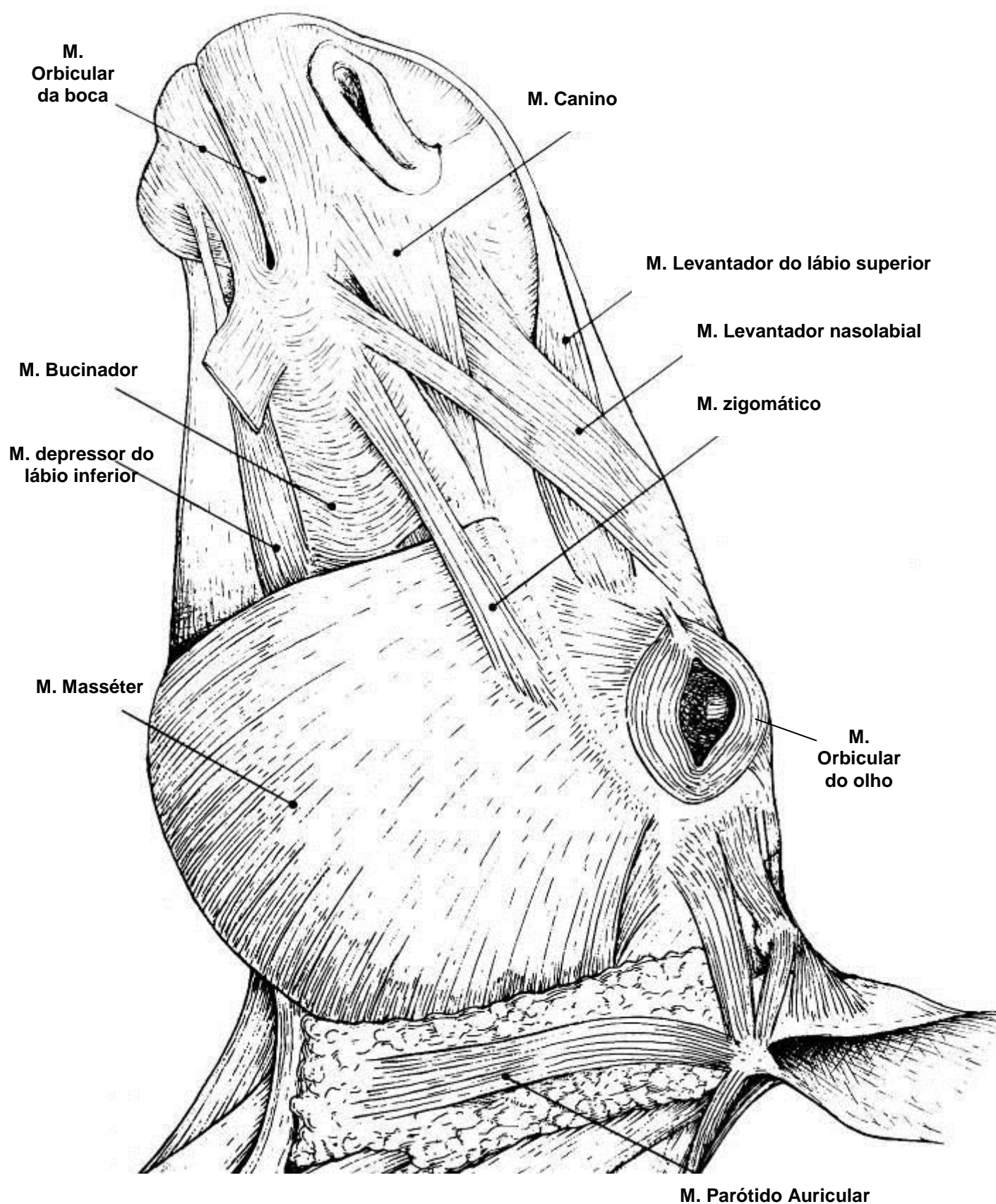


APARELHO LOCOMOTOR

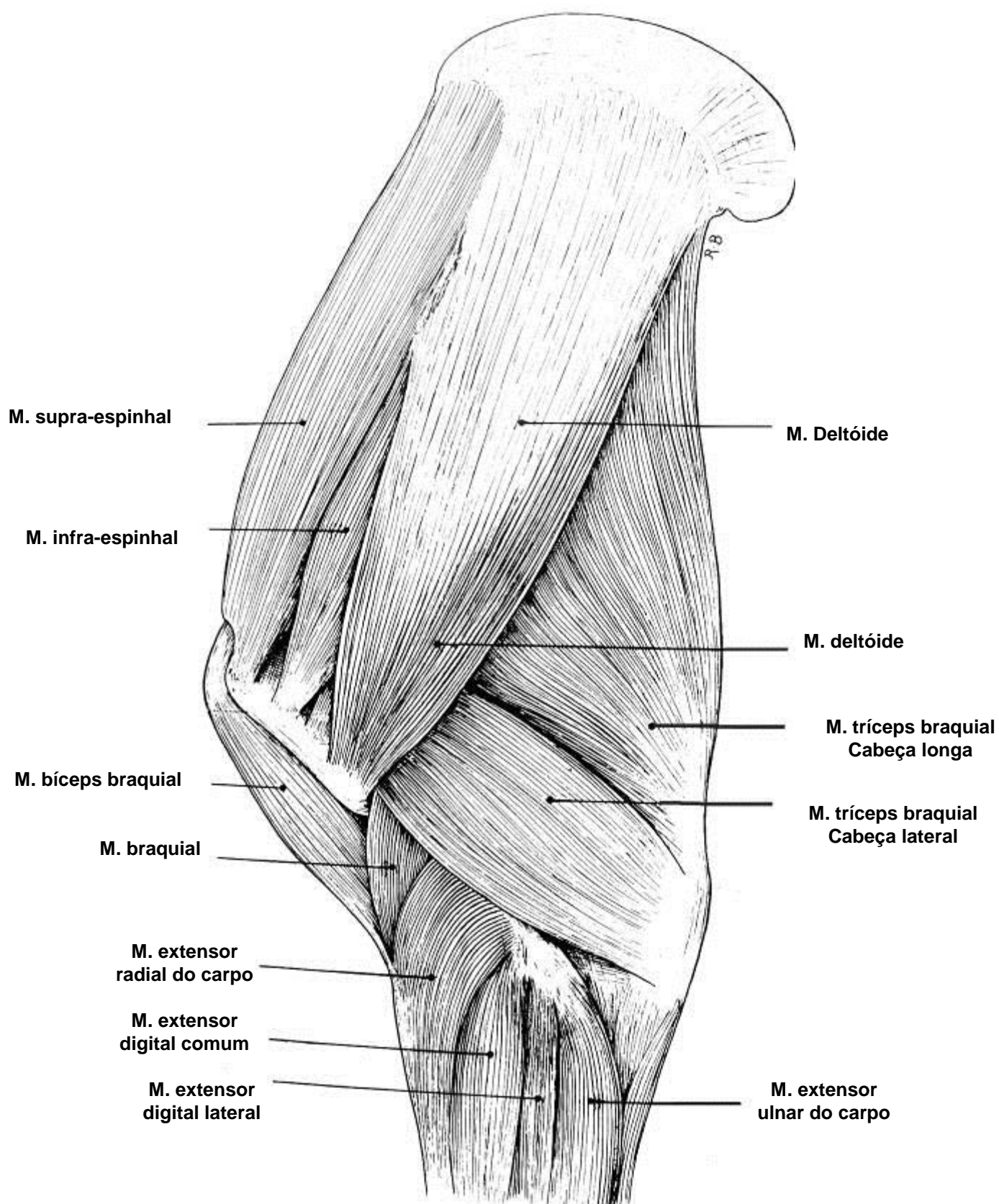
MIOLOGIA

MÚSCULOS SUPERFICIAIS DA CABEÇA DO EQUINO

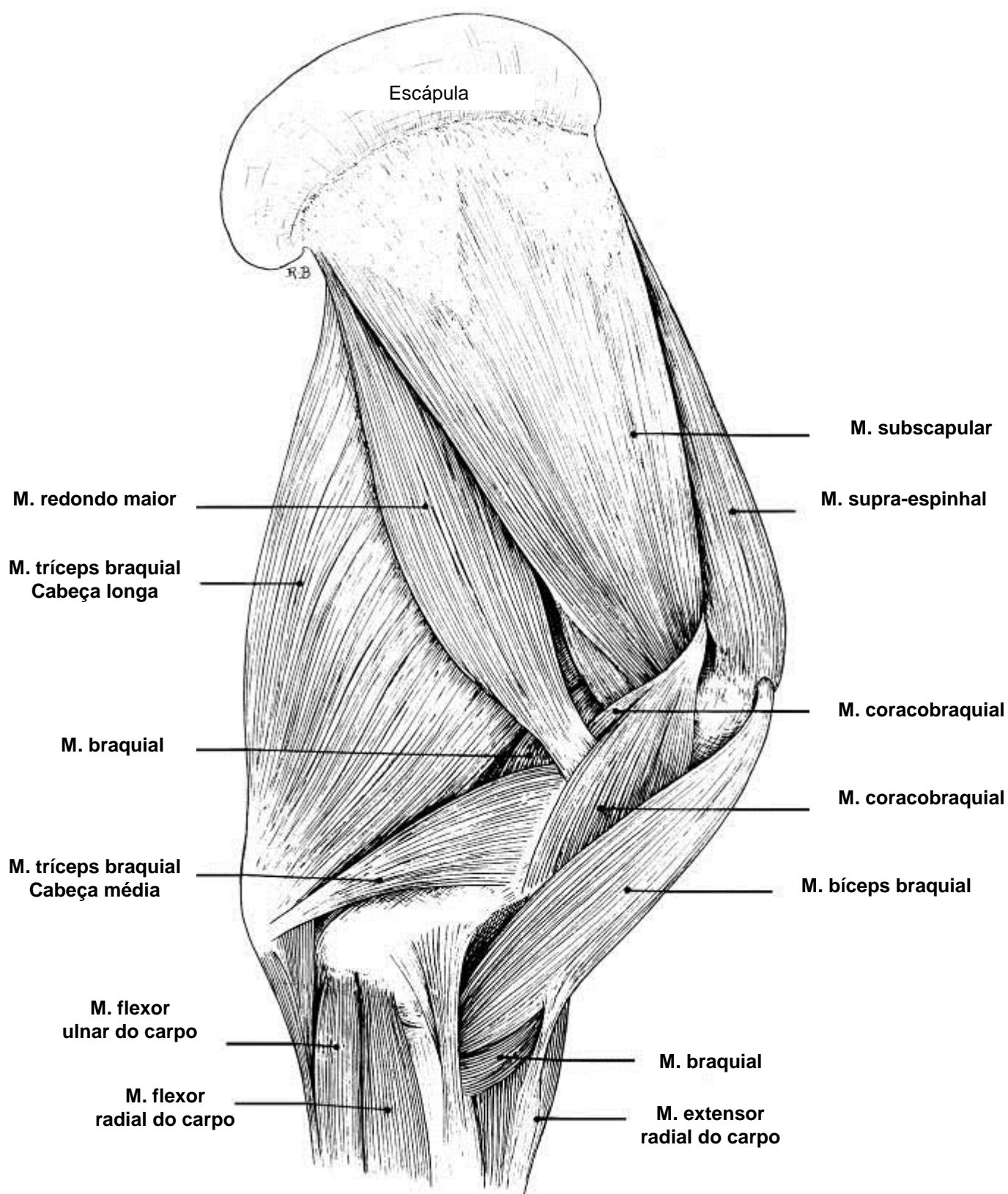
Vista Lateral



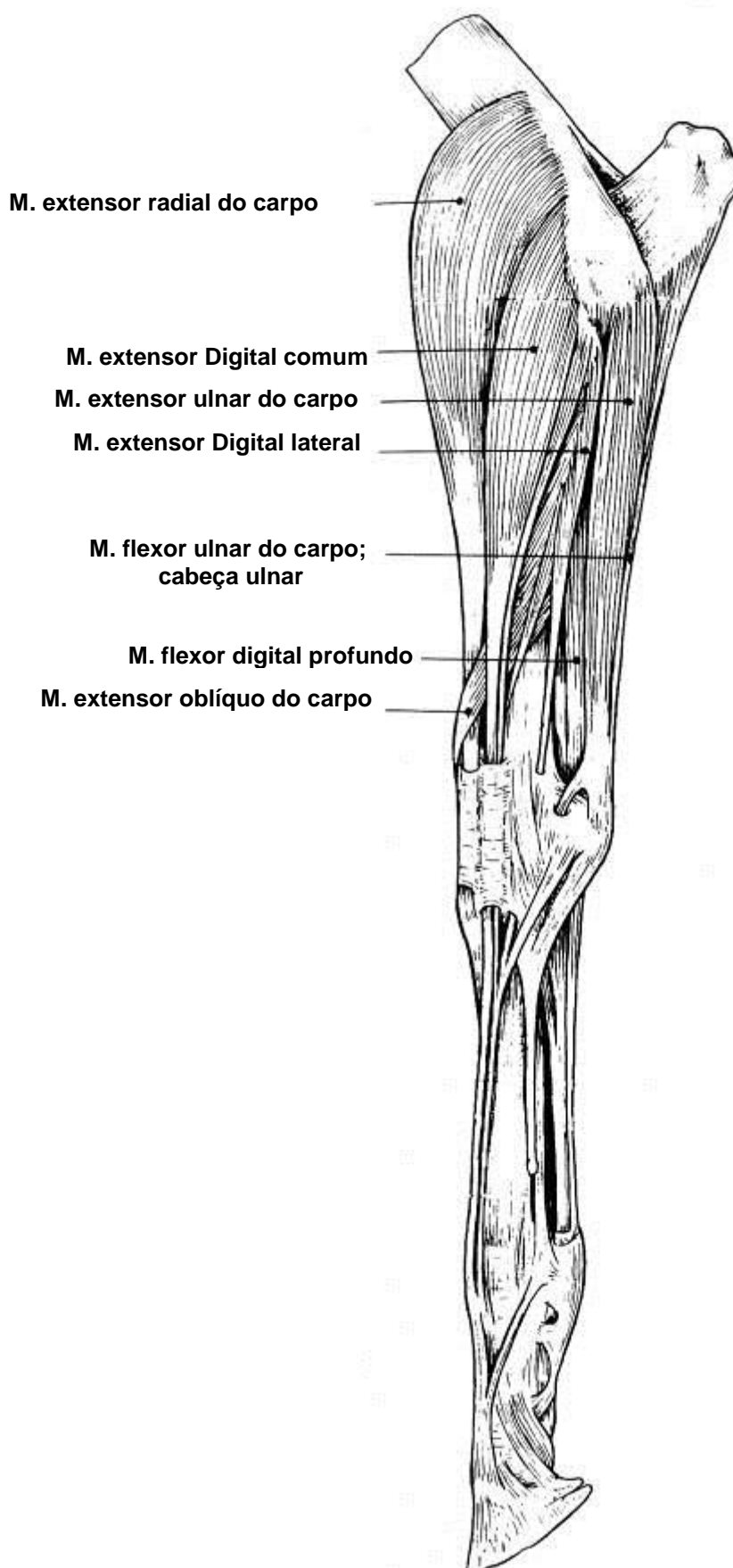
MÚSCULOS DO MEMBRO TORÁCICO DO EQUINO VISTA LATERAL



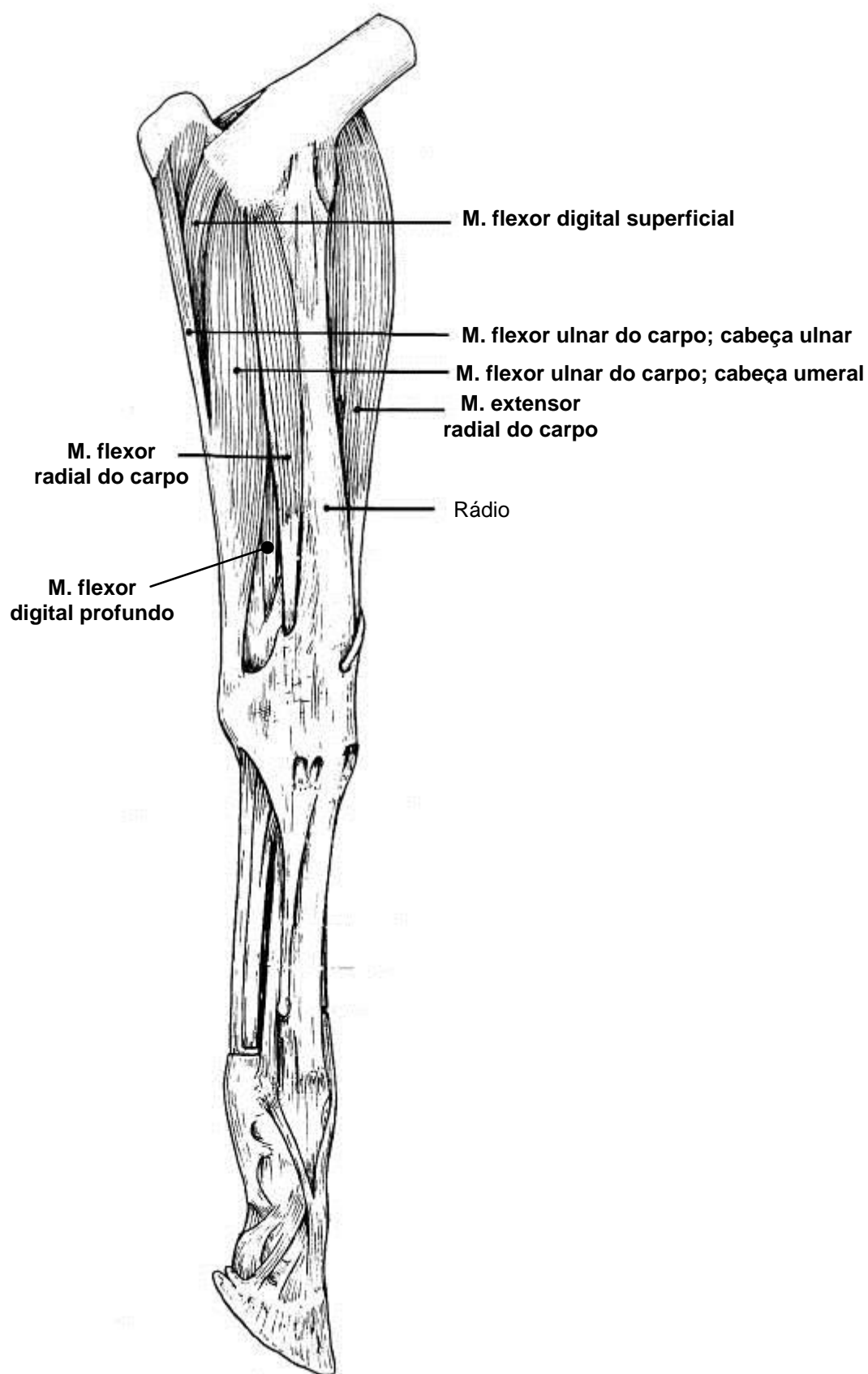
MÚSCULOS DO MEMBRO TORÁCICO DO EQUINO VISTA MEDIAL



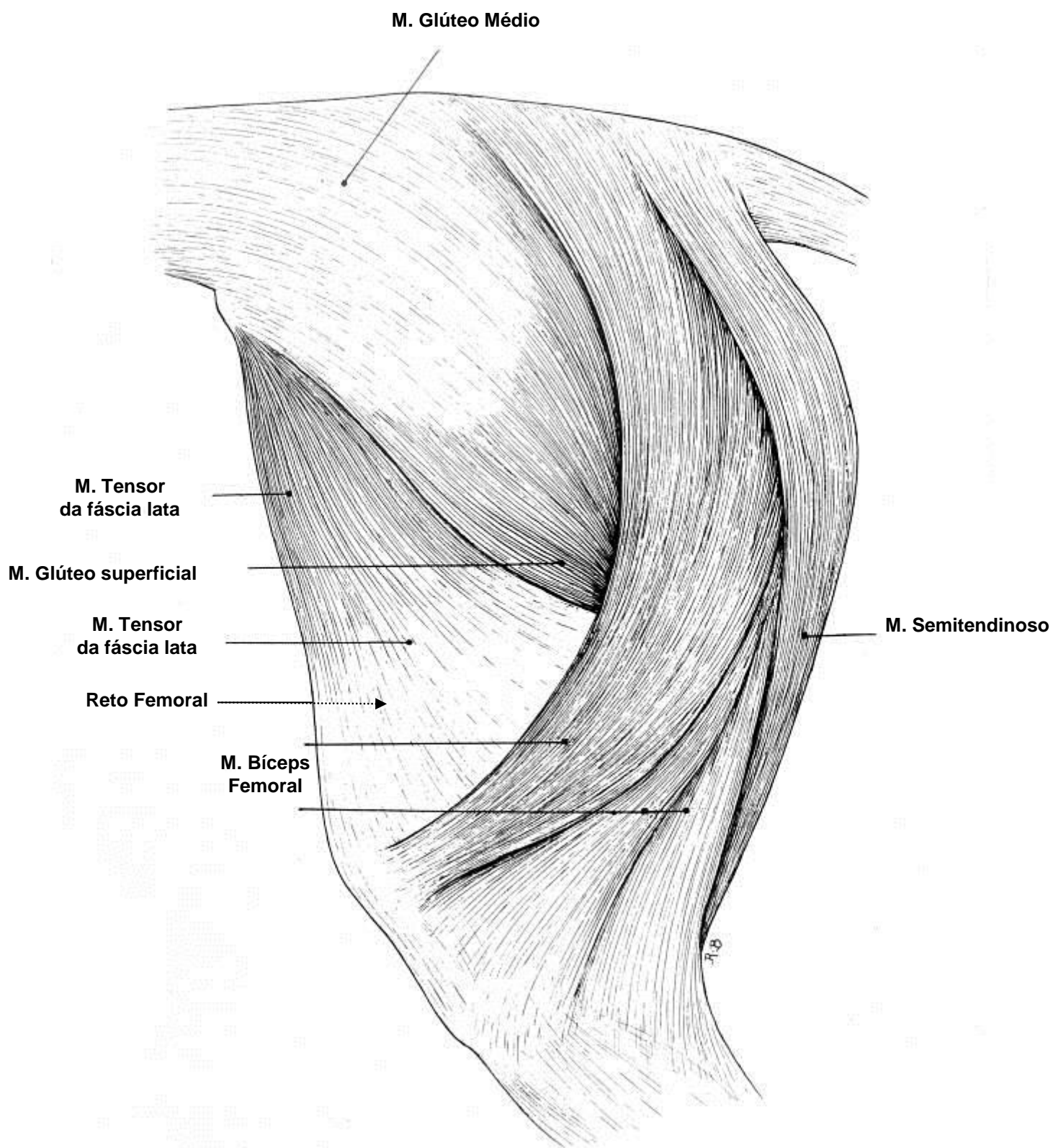
VISTAS LATERAL DOS MÚSCULOS SUPERFICIAIS **DA REGIÃO DO ANTEBRAÇO DO EQUINO**



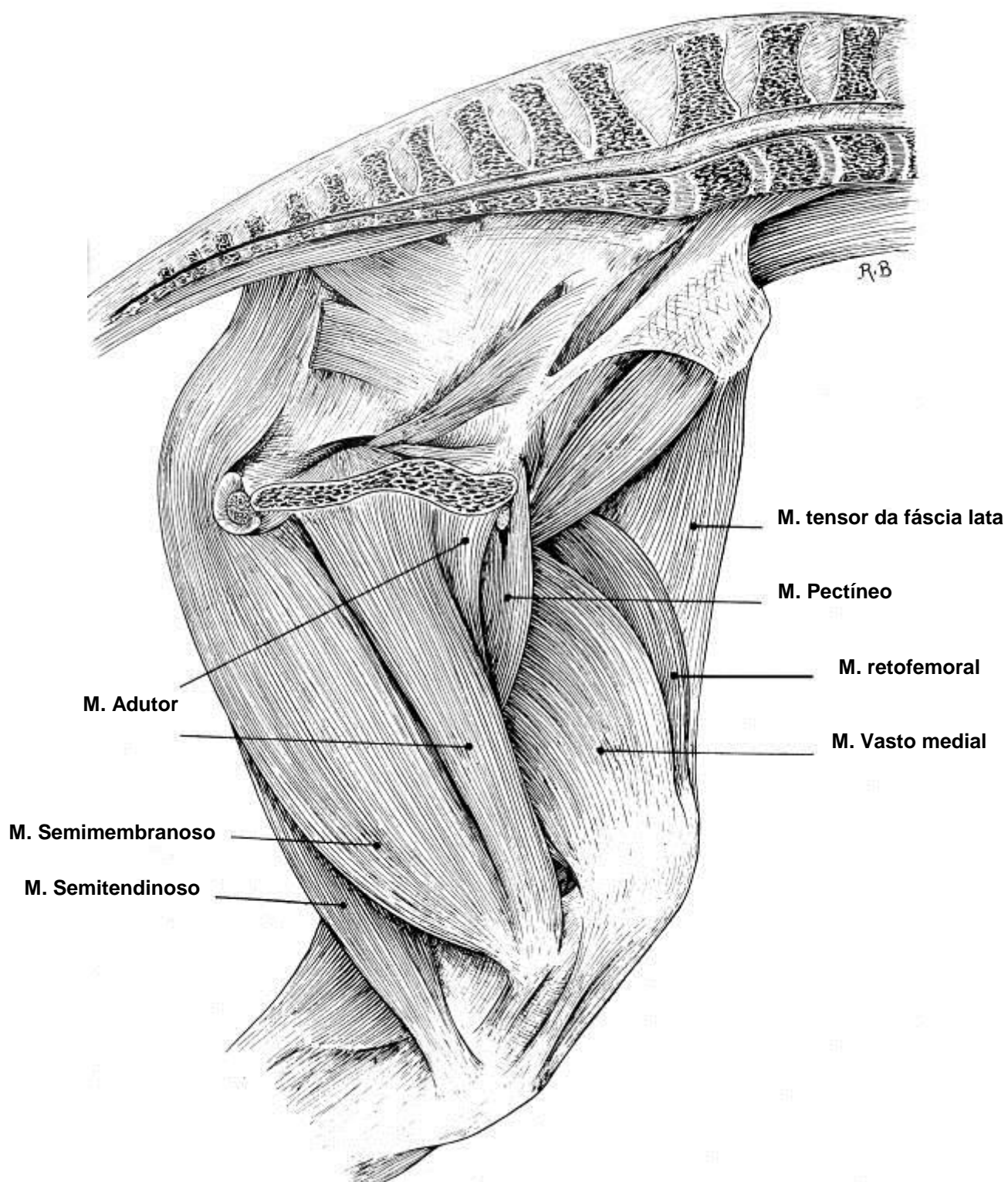
VISTAS MEDIAL DOS MÚSCULOS SUPERFICIAIS **DA REGIÃO DO ANTEBRAÇO DO EQUINO**



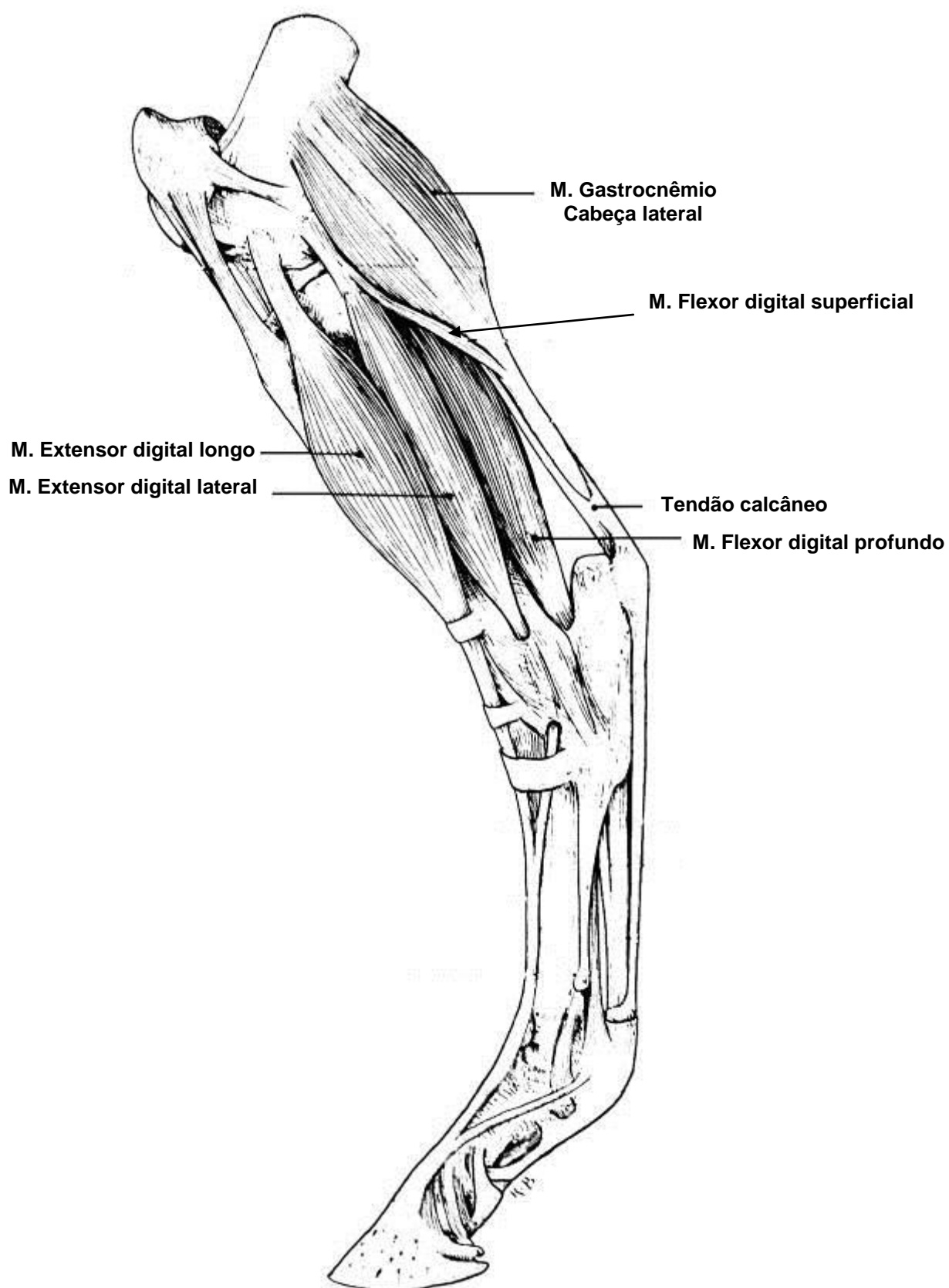
MÚSCULOS DO MEMBRO PÉLVICO DO EQUINO VISTA LATERAL



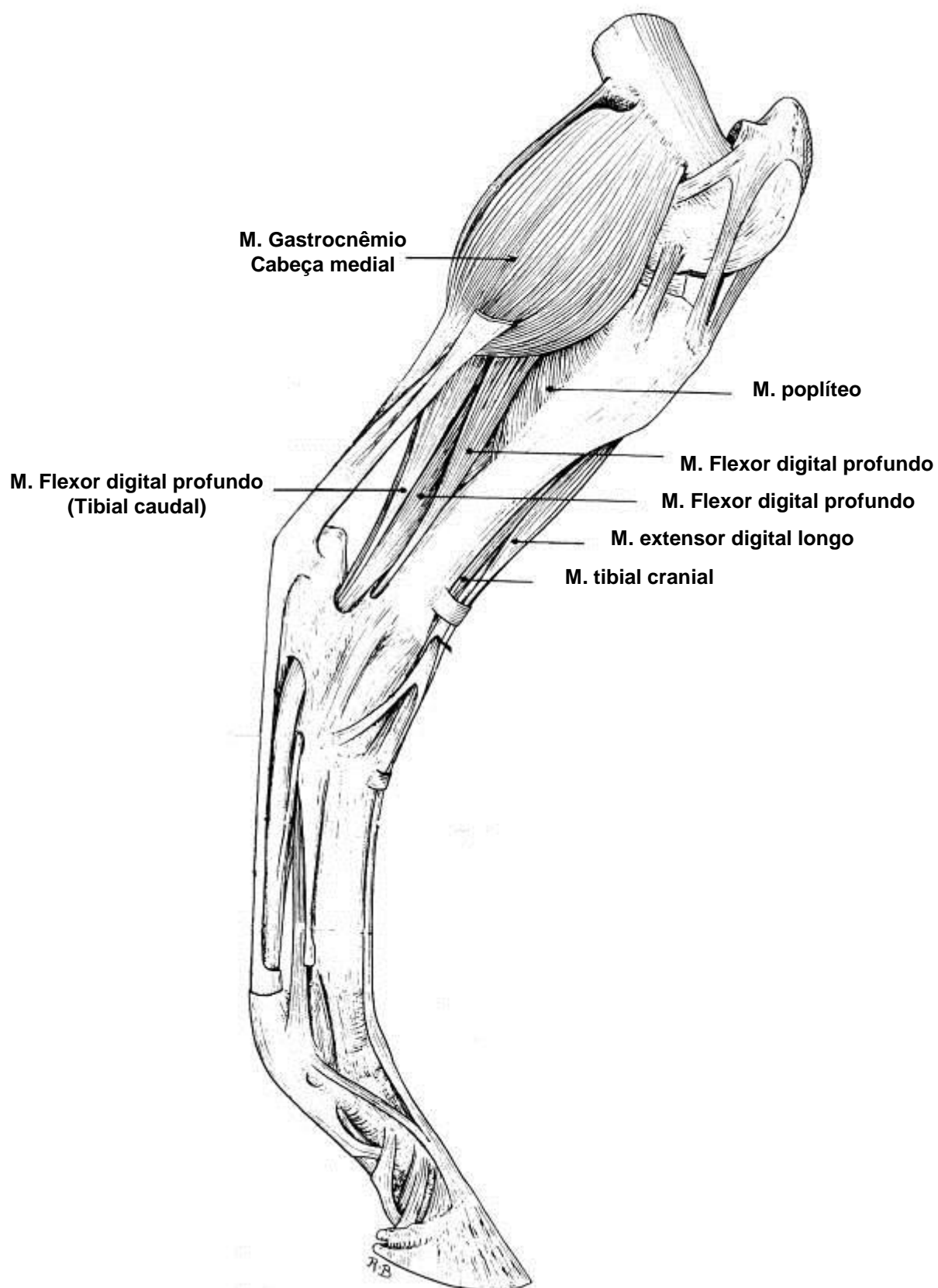
MÚSCULOS DO MEMBRO PÉLVICO DO EQUINO VISTA MEDIAL



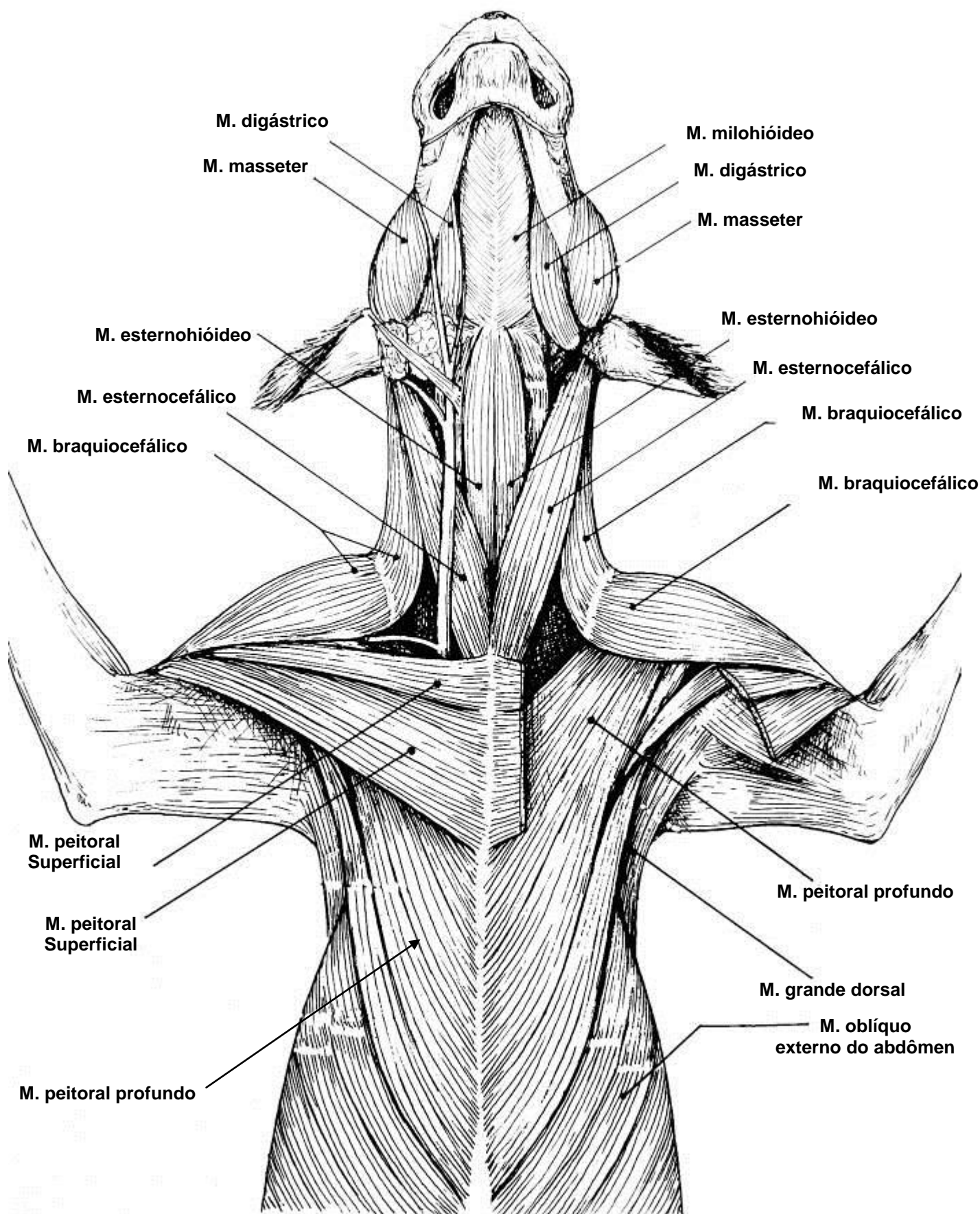
VISTA LATERAL DOS MÚSCULOS
DA REGIÃO CRURAL (PERNA) DO EQUINO



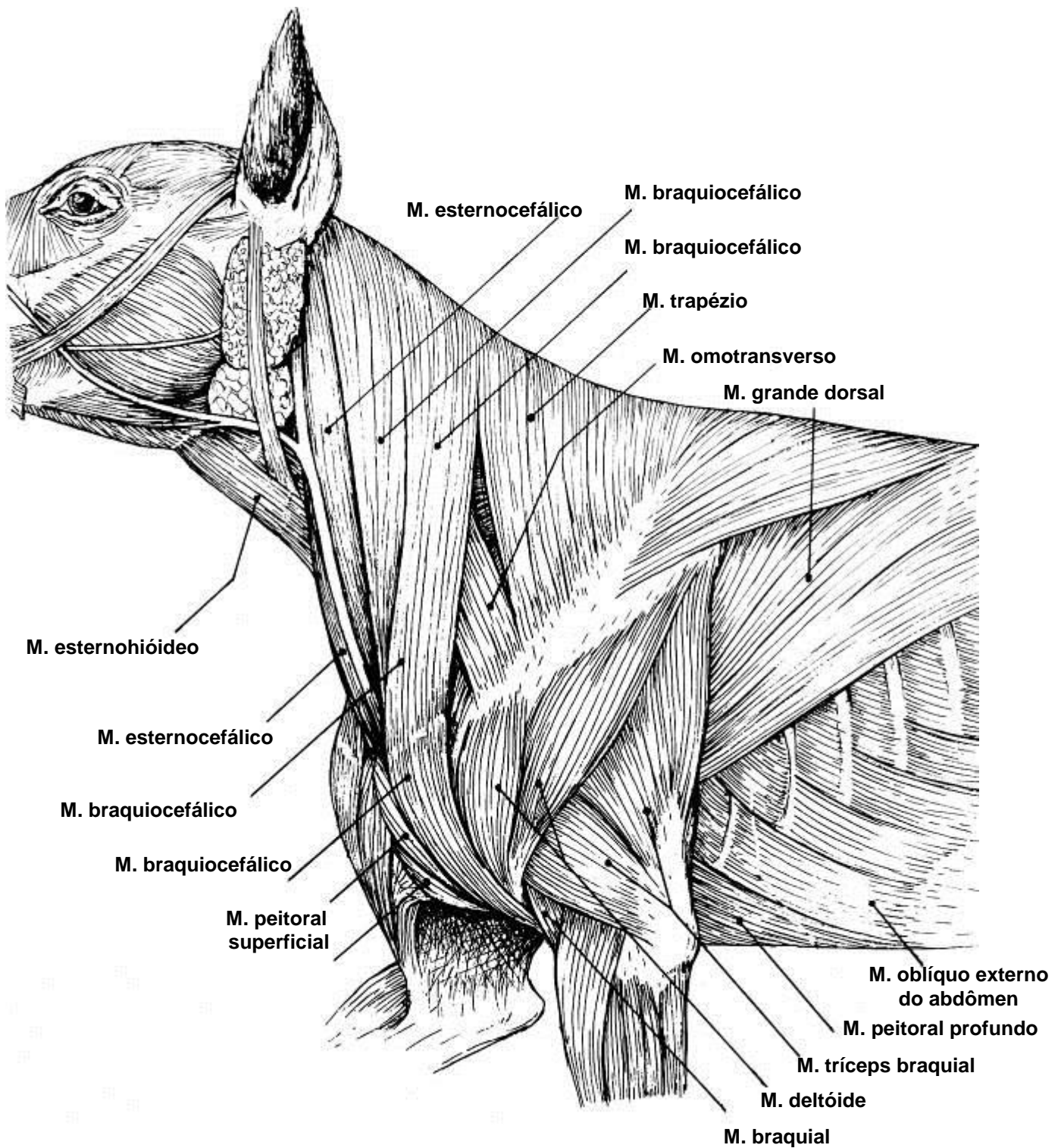
VISTA MEDIAL DOS MÚSCULOS
DA REGIÃO CRURAL (PERNA) DO EQUINO



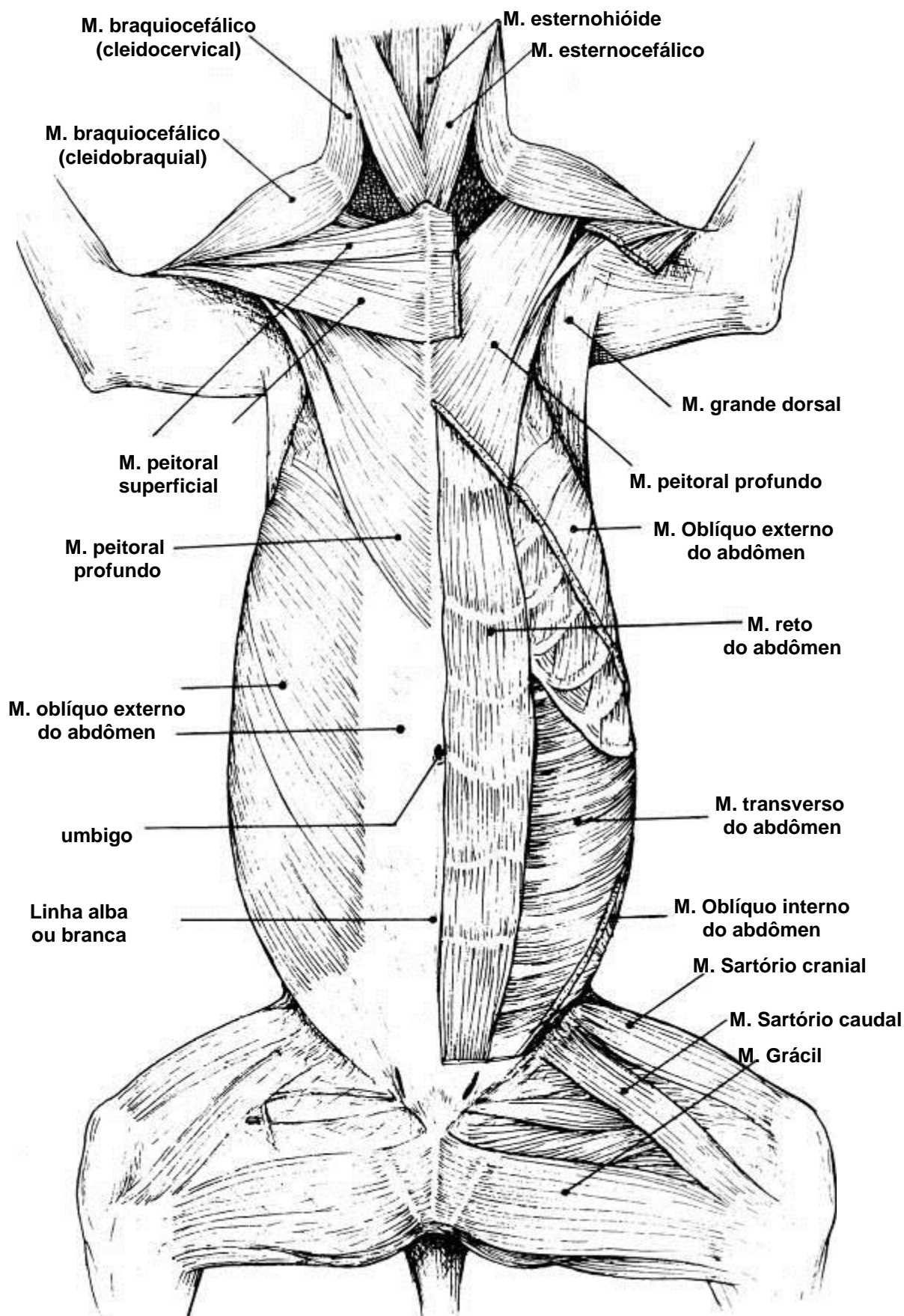
VISTA VENTRAL DOS MÚSCULOS SUPERFICIAIS DA CABEÇA, PESCOÇO E TÓRAX DO CÃO



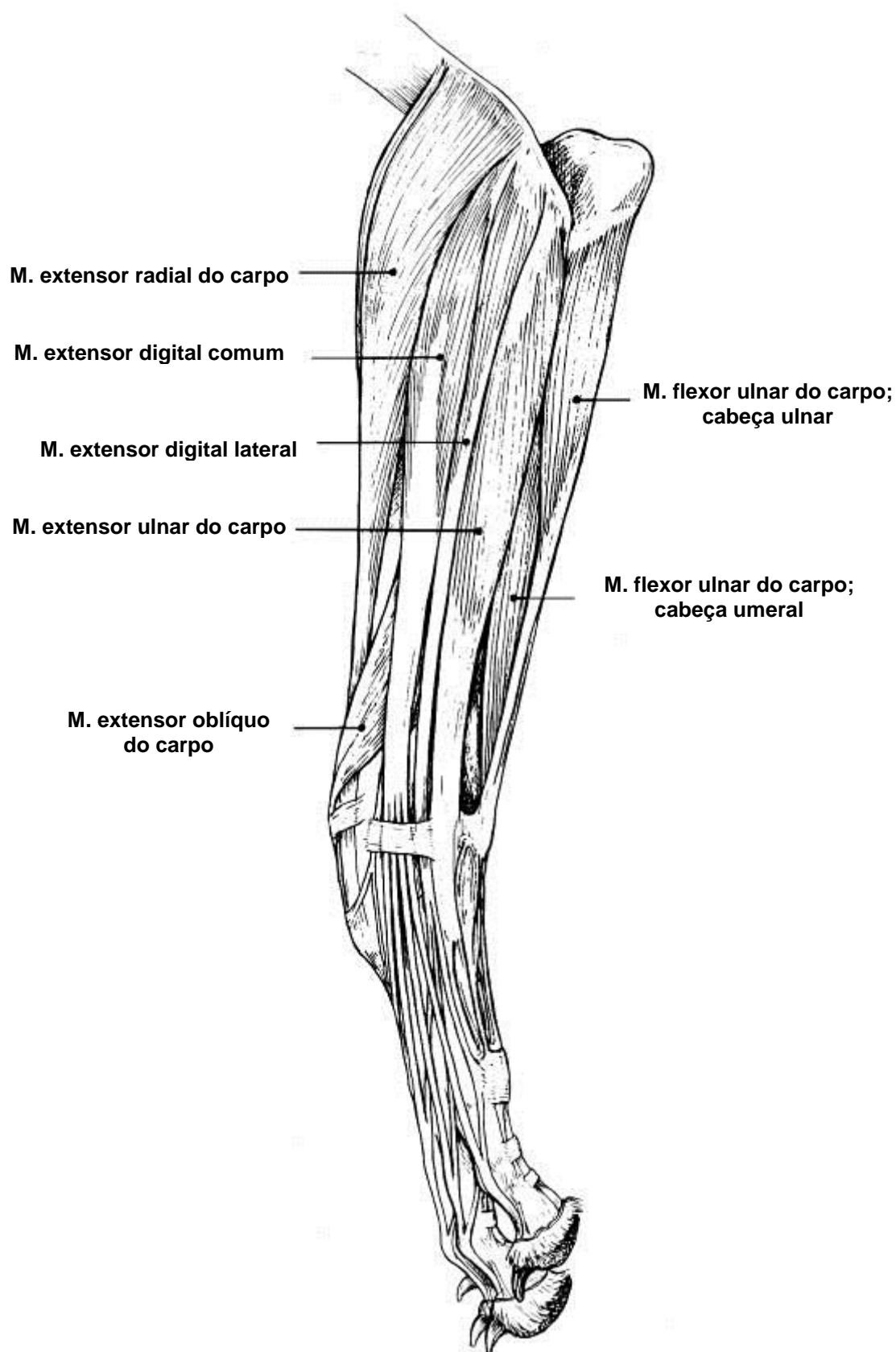
VISTA LATERAL DOS MÚSCULOS SUPERFICIAIS DO PESCOÇO E TÓRAX DO CÃO



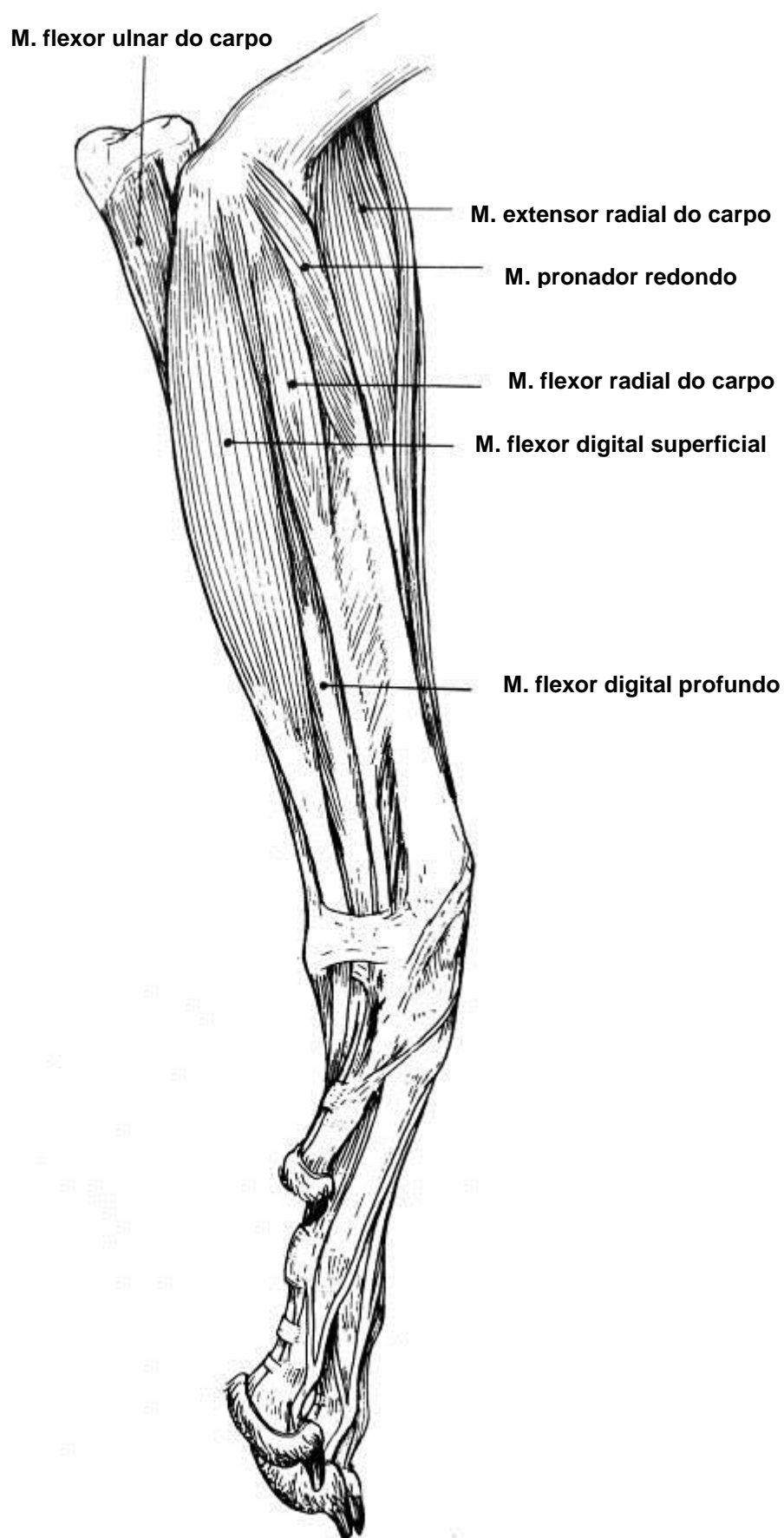
VISTA VENTRAL DOS MÚSCULOS SUPERFICIAIS DO PESCOÇO, TÓRAX, ABDÔMEN E REGIÃO FEMORAL DO CÃO



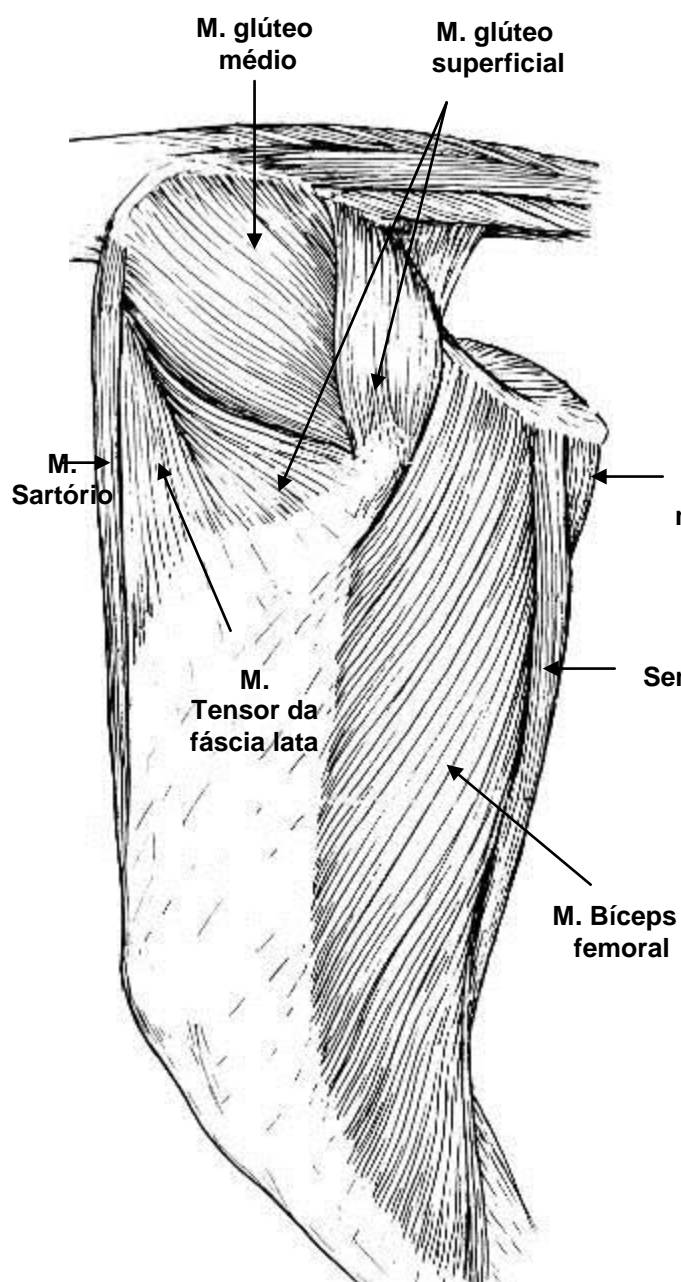
VISTA LATERAL DOS MÚSCULOS SUPERFICIAIS DO ANTEBRAÇO DO CÃO



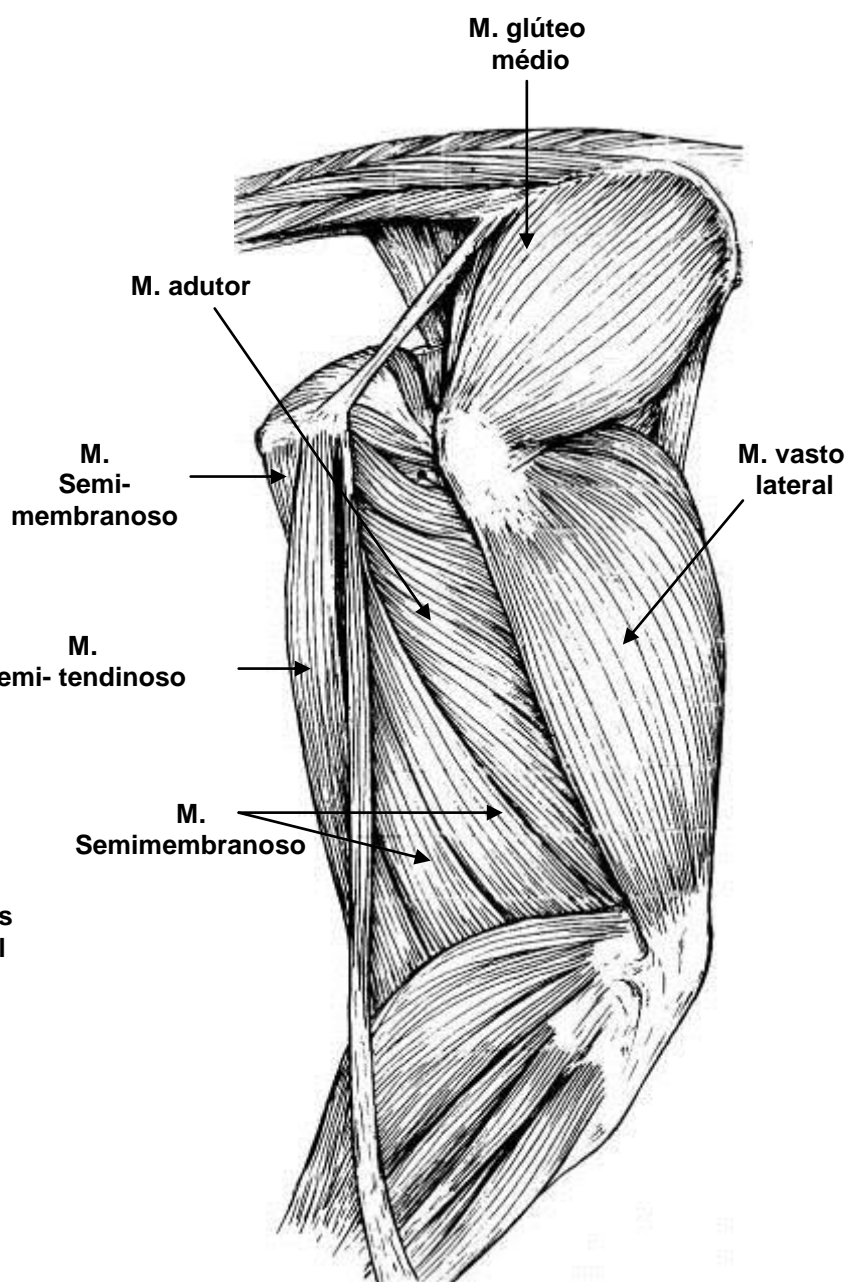
VISTA LATERAL DOS MÚSCULOS SUPERFICIAIS DO ANTEBRAÇO DO CÃO



VISTA LATERAL DOS MÚSCULOS DA REGIÃO DA ARTICULAÇÃO COXAL E FEMORAL DO CÃO

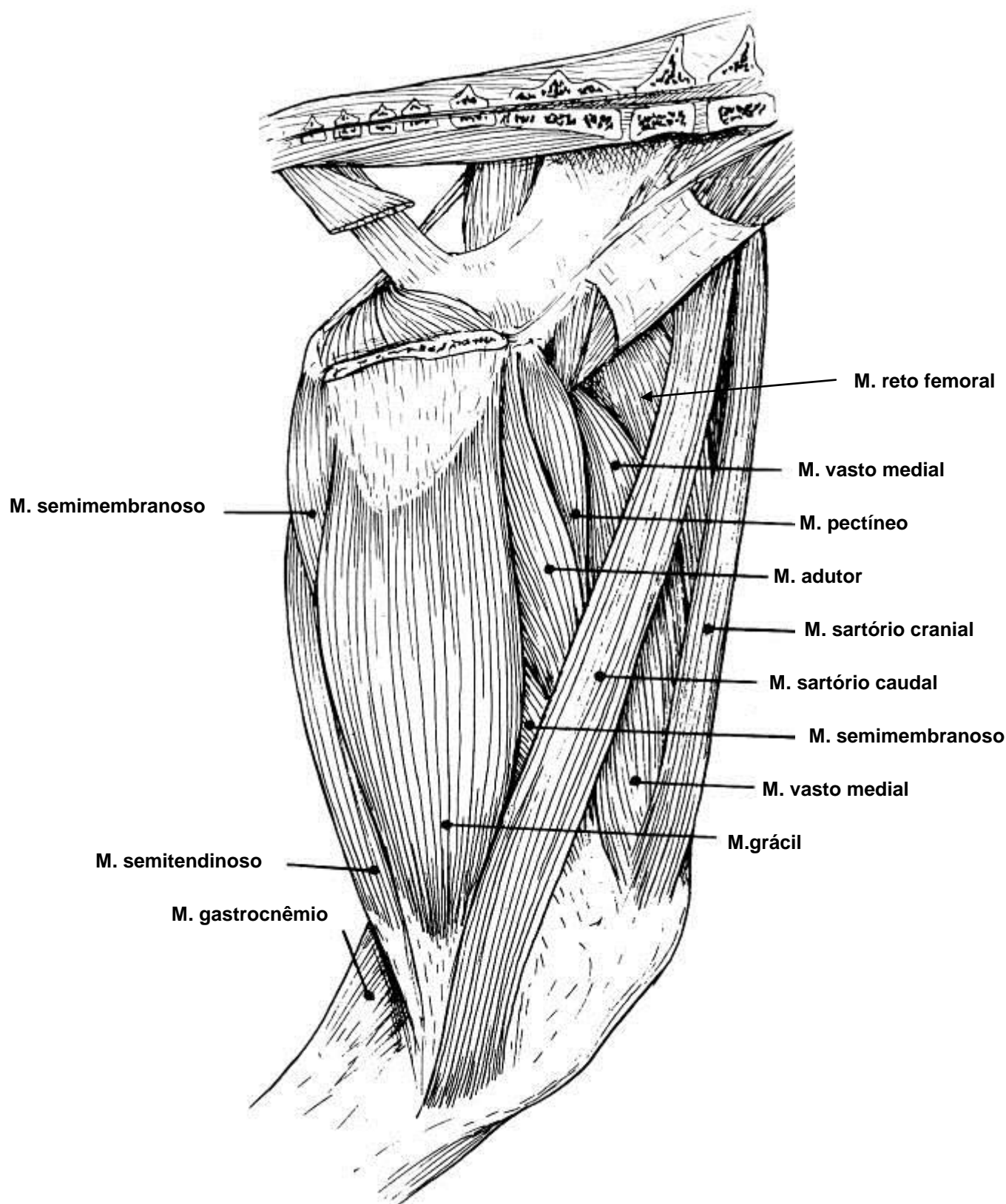


músculos superficiais

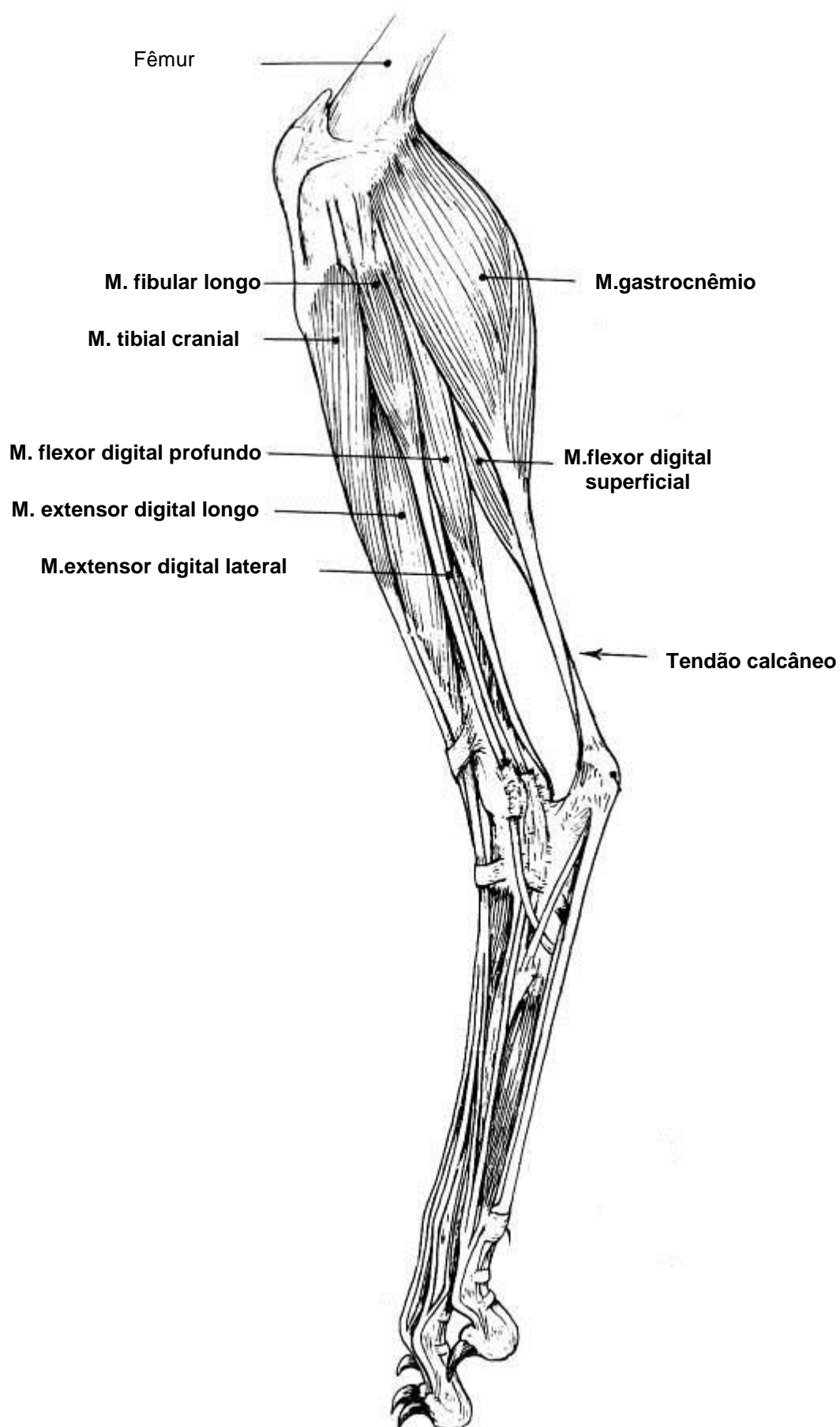


músculos profundos

**VISTA MEDIAL DOS MÚSCULOS DA REGIÃO
DA ARTICULAÇÃO COXAL E FEMORAL DO CÃO**



VISTA LATERAL DOS MÚSCULOS SUPERFICIAIS DA REGIÃO CRURAL (PERNA) DO CÃO



VISTA MEDIAL DOS MÚSCULOS SUPERFICIAIS
DA REGIÃO CRURAL (PERNA) DO CÃO

