

Pharyngeal and Esophageal Disorders

Deborah J. Davenport

Michael S. Leib

Rebecca L. Remillard

*“The Chinese do not draw any distinction between food and medicine.”
Lin Yutang*

CLINICAL IMPORTANCE

Compared with vomiting and diarrhea, swallowing disorders are relatively uncommon in dogs and cats. However, these conditions are often profoundly debilitating due to undernutrition (i.e., lack of adequate food intake) and recurrent pulmonary infections resulting from aspiration. Pharyngeal and esophageal disorders most commonly encountered include: 1) motility disorders (e.g., cricopharyngeal achalasia, megaesophagus), 2) inflammatory disorders (e.g., esophagitis, gastroesophageal reflux) and 3) obstructive lesions (e.g., vascular ring anomalies, strictures and foreign bodies).

PATIENT ASSESSMENT

History and Physical Examination

Congenital pharyngeal and esophageal disorders are typically diagnosed in young animals soon after weaning. In some young dogs, clinical and subclinical esophageal dysmotility may improve with age, whereas the disorder progresses in other patients (Bexfield et al, 2006). Rarely, dogs with congenital malformations of the aortic arches, also known as vascular ring anomalies, may present with late-onset regurgitation as adults (Fingeroth and Fossum, 1987; Muldoon et al, 1997).

Acquired pharyngeal and esophageal disease can affect dogs and cats of any age. Owners of pets presenting for suspected pharyngeal and esophageal disorders should be asked about

feeding dental chew treats (Leib and Sartor, 2008), bones or bone and raw food diets, which can result in esophageal foreign bodies. The history of a recent anesthetic procedure may suggest reflux esophagitis (Wilson et al, 2005). Owners of cats presenting with signs of esophageal disease should be asked about recent oral antibiotic administration (Westfall et al, 2001; Beatty et al, 2006; German et al, 2005).

Owners of dogs with dysphagia due to pharyngeal disease typically report coughing or gagging as the dog chews and swallows its food. In dogs and cats, the hallmark of an esophageal disorder is regurgitation (**Box 50-1**). Additional clinical signs include ptyalism, frequent swallowing, gurgling esophageal noises, halitosis and apparent pain on swallowing. Affected cats may vocalize in conjunction with gagging or regurgitation. The frequency of regurgitation is variable. Owners may report immediate postprandial regurgitation of undigested food, water or saliva or describe signs manifested several hours after feeding. Affected dogs and cats often have a voracious appetite despite regurgitation unless they have secondary aspiration pneumonia. Dyspnea, coughing, weakness and fever may be referable to severe respiratory compromise associated with aspiration pneumonia.

Esophageal disorders may be associated with neuromuscular diseases and endocrinopathies. Owners may describe their pets as being weak or uncoordinated. The evidence for association of megaesophagus and hypothyroidism is tenuous and uncommon.

Poor body condition is often evident (body condition score [BCS] 1/5 or 2/5). Body condition should be monitored close-

Box 50-1. Regurgitation vs. Vomiting.

Differentiating regurgitation from vomiting is important in distinguishing esophageal from gastric disease. Characteristics of vomiting include expulsion of digested and bile-stained food and retching with involuntary abdominal contractions. Gastric contents are often highly acidic, which may be reflected in the pH of the vomitus. However, vomiting often involves reflux of bicarbonate-rich fluid into the stomach from the duodenum, which buffers gastric acid. The vomited material may then have a neutral or near-neutral pH.

Regurgitation involves less forceful casting up of tubular, bile-free, undigested food. Mucoïd secretions mixed with the undigested food will usually have a pH of 6.5 to 7.0. Copious salivation may also be a confusing sign; it may be a primary sign of esophageal diseases (e.g., foreign body) or it may be part of the nausea that often accompanies vomiting.

The Bibliography for **Box 50-1** can be found at www.markmorris.org.

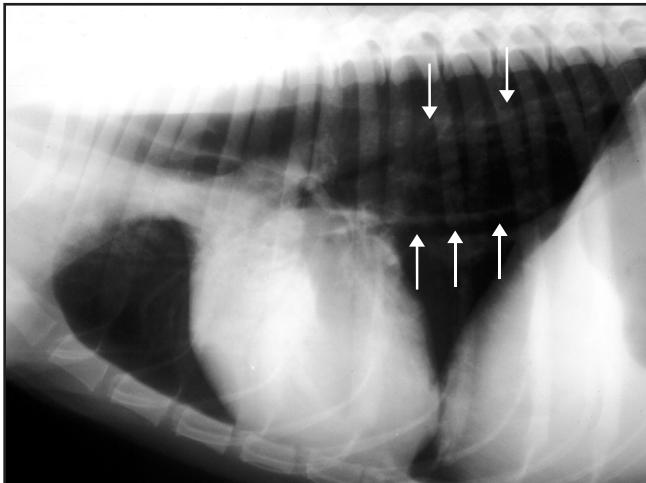
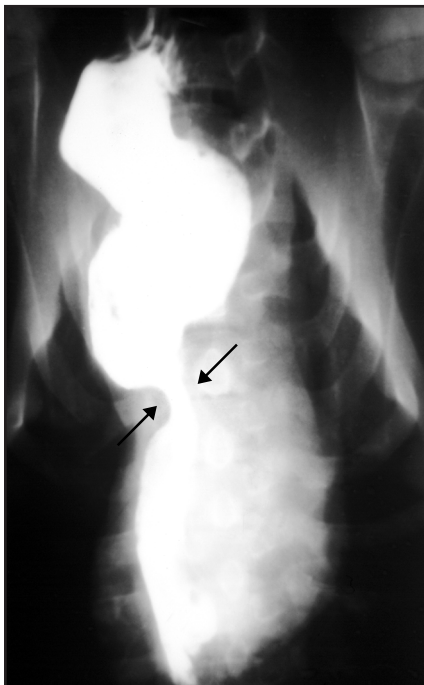


Figure 50-1. Lateral thoracic radiograph demonstrating esophageal dilatation in a dog with acquired megaesophagus. The arrows depict the dorsal and ventral margins of the dilated esophagus. (Courtesy Dr. Joanne Burns, Veterinary Imaging Services, Topeka, KS.)

Figure 50-2. Ventrodorsal thoracic radiograph with a positive-contrast esophagram demonstrating an esophageal stricture due to a persistent right aortic arch in a puppy. Note the narrowed esophageal lumen at the base of the heart (arrows) and dilatation of the esophagus on either side of the obstruction.



ly during reassessment and the BCS should be recorded. Young patients with congenital megaesophagus, vascular ring anomalies or cricopharyngeal dysphagia are often stunted compared to littermates.

Auscultatory findings often indicate secondary aspiration pneumonia and may include crackles and prominent bronchovesicular sounds. Dogs with aspiration pneumonia may be febrile and have a mucopurulent nasal discharge.

A complete neurologic examination should be performed on adult dogs with swallowing disorders because acquired megaesophagus is often associated with neuromuscular disorders. Signs of lower motor neuron disease may provide evidence of a generalized polymyopathy, polyneuropathy or neuromuscular junctionopathy (e.g., myasthenia gravis).

Laboratory and Other Clinical Information

A complete blood count may provide evidence of aspiration pneumonia and some sense of the severity of infection. In chronically affected patients, serum protein and albumin concentrations may provide an indication of nutritional status. Additionally, other serum biochemical abnormalities may provide evidence for an underlying disorder (e.g., hypoadrenocorticism, hypothyroidism).

Radiography is a vital diagnostic aid for evaluating dogs and cats with suspected swallowing and esophageal disorders. Survey films may provide definitive information in cases of megaesophagus and esophageal foreign bodies (**Figure 50-1**). Radiographic findings in dogs and cats with megaesophagus include a dilated, air-filled esophagus. In the case of vascular ring anomalies, characteristic esophageal dilatation proximal to the heart base can be identified. Thoracic radiography also allows the clinician to assess the patient for aspiration pneumonia. Additionally, thoracic films may reveal a cranial thoracic mass. Thymoma and thymic lymphosarcoma have been associated with secondary acquired megaesophagus and generalized inflammatory myopathies.

An esophagram offers additional diagnostic information, especially in cases of obstructive lesions, esophagitis and esophageal hypomotility without megaesophagus (**Figure 50-2**). When coupled with video fluoroscopy, an esophagram allows sensitive evaluation of the swallow reflex and esophageal motility (Bexfield et al, 2006) (**Figure 50-3**).

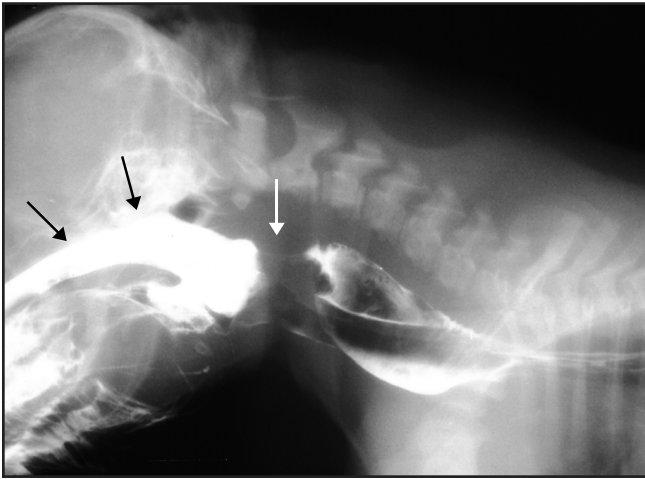


Figure 50-3. Cricopharyngeal achalasia in a cocker spaniel puppy presented for dysphagia. A barium swallow (Left) demonstrated that the cricopharyngeal region (white arrow) did not relax normally during swallowing, which resulted in reflux of barium into the nasopharynx (black arrows). Only a small amount of barium entered the esophagus. The puppy had a difficult time swallowing liquids as shown by regurgitation of milk back through the nose (Right). (Courtesy Dr. Philip Roudebush, Topeka, KS.)

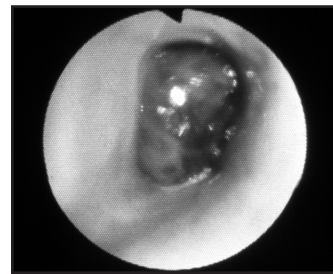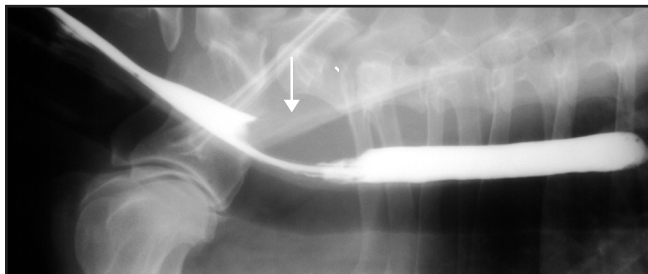


Figure 50-4. Positive-contrast esophagram (Left) from a 12-year-old mixed-breed dog presented for worsening regurgitation. A filling defect is noted in the dorsal wall of the esophagus (arrow). Endoscopy demonstrated a mass lesion (Right) that was confirmed by examination of biopsy specimens as a squamous cell carcinoma. This lesion developed at the site of an acquired esophageal stricture secondary to an episode of postsurgical gastroesophageal reflux. (Courtesy Dr. Michael Leib, Virginia-Maryland Regional College of Veterinary Medicine, Blacksburg, VA.)

Esophagoscopy is a valuable tool for evaluating dogs and cats with suspected obstructive, neoplastic or inflammatory lesions of the esophagus and pharynx (Figure 50-4). This tool allows visualization of the entire area and collection of tissue specimens for microbiologic and histopathologic examination, if indicated. Additionally, in cases of esophageal foreign bodies or strictures, the flexible endoscope can provide definitive treatment of the lesion. Foreign bodies can be retrieved or pushed into the stomach using a variety of forceps, whereas esophageal strictures are best managed with endoscopic bougienage, balloon dilatation or both procedures (Weyrauch and Willard, 1998; Leib et al, 2001).

Acquired megaesophagus can occur secondary to several neuromuscular disorders such as myasthenia gravis, dysautonomia, hypothyroidism, hypoadrenocorticism, systemic lupus erythematosus and other causes of generalized myopathy or neuropathy (Dewey et al, 1995; Shelton, 1996, 1996a; Gaynor et al, 1997; Bartges and Nielson, 1992; Harkin et al, 2002).^a Consult internal medicine and gastroenterology textbooks for a more complete discussion of the diagnosis of these disorders.

Risk Factors

Swallowing disorders have been thought to occur rarely in cats. However, several recent reports have described esophagitis and esophageal strictures in cats after administration of oral antibiotics (tetracycline, doxycycline and clindamycin) (Leib et al, 2001; Beatty et al, 2006; German et al, 2005). Cats may also develop esophageal disease as a result of anesthesia-associated gastroesophageal reflux (Pearson et al, 1978; Leib et al, 2001), gastroesophageal reflux disease (Han et al, 2003) and foreign bodies (Augusto et al, 2005).

In dogs, risk factors for swallowing disorders are primarily breed and age related. Several breeds appear to be predisposed to the development of congenital disorders such as cricopharyngeal dysphagia, congenital megaesophagus and vascular ring anomalies (Table 50-1).

No gender predisposition for idiopathic acquired swallowing disorders is apparent. The condition, however, occurs more often in large-breed dogs (Leib and Hall, 1984). One report indicated that Great Dane, golden retriever, German shepherd and Irish setter dogs are at risk for the disease (Gaynor et al,

Table 50-1. Breed-associated disorders of the pharynx and esophagus.

Conditions	Breeds
Cricopharyngeal dysphagia	Cocker spaniel
Congenital esophageal dysmotility and/or megaesophagus	Bouvier des Flandres
	Chinese Shar-Pei
	Fox terrier and other terrier breeds
	German shepherd dog
	Great Dane
	Irish setter
	Labrador retriever
	Miniature schnauzer
	Newfoundland
	Siamese cat
Idiopathic acquired megaesophagus	German shepherd dog
	Golden retriever
	Great Dane
	Irish setter
Vascular ring anomalies	Boston terrier
	English bulldog
	German shepherd dog
	Irish setter
	Labrador retriever
	Poodle

Table 50-2. Mechanisms of pharyngeal and esophageal disorders.

Mechanisms	Disorders
Aberrant motility	Congenital megaesophagus
	Cricopharyngeal dysphagia
	Dysautonomia
	Endocrinopathies (hypothyroidism, hypoadrenocorticism)
	Esophageal dysmotility in young dogs
	Extraluminal obstruction (mediastinal or hilar lymphadenopathy)
	Idiopathic megaesophagus
	Infectious diseases (canine distemper)
	Myasthenia gravis
	Paraneoplastic syndromes (lymphosarcoma, thymoma)
	Polymyopathies
	Polyneuropathies
	Secondary megaesophagus
	Toxin ingestion (lead)
Inflammatory conditions	Foreign body esophagitis
	Pharyngitis
	Reflux esophagitis
Obstructive lesions	Foreign bodies
	Neoplasia
	<i>Spirocerca lupi</i> granulomas
	Strictures
	Vascular ring anomalies

1997). Middle-aged to older dogs are more likely to develop myasthenia gravis and other neuromuscular disorders resulting in esophageal disease. Nearly 90% of dogs with focal or generalized myasthenia gravis develop megaesophagus (Shelton et al, 1990). In addition, those breeds predisposed to endocrinopathies (e.g., hypothyroidism and hypoadrenocorticism) are at risk for development of megaesophagus as a rare manifestation of their disease. Dogs with laryngeal paralysis are also

at risk for development of megaesophagus (Gaynor et al, 1997). In certain areas (e.g., northeastern United States), exposure to lead has been linked to cases of secondary acquired megaesophagus. In the Midwest, dysautonomia may be associated with acquired megaesophagus (Harkin et al, 2002).

Etiopathogenesis

Pharyngeal and esophageal disorders can generally be attributed to one of three basic pathophysiologic mechanisms: aberrant motility, obstructive lesions or inflammatory degenerative conditions that cause esophagitis/gastroesophageal reflux (Table 50-2) (Twedt, 1995).

Aberrant Motility

Cricopharyngeal dysphagia is characterized by asynchrony of the swallowing reflex (Papazoglou et al, 2006). In this condition, the cricopharyngeal muscle fails to relax in coordination with pharyngeal muscle contractions, thus preventing passage of a food bolus from the oropharynx to the esophagus.

Historically, dogs with megaesophagus were presumed to have esophageal achalasia. In this condition, the lower esophageal sphincter fails to relax as esophageal peristaltic activity delivers food to the gastroesophageal junction (GEJ). However, lower esophageal sphincter pressure is normal and activity is synchronous with esophageal motility in dogs with congenital and acquired megaesophagus. The work of several investigators suggests that the efferent pathway in many dogs with megaesophagus is functional, whereas the afferent pathway is dysfunctional (Tan and Diamant, 1987; Holland et al, 1993, 1994). Using intraluminal balloon distention, investigators demonstrated that dogs with idiopathic megaesophagus have a defect in their afferent neural pathway (Washabau, 1992). Other investigators have suggested a defect in esophageal compliance (Holland et al, 1993). These findings have clinical implications because they suggest that foods containing more bulk or prepared in larger boluses may have the capacity to stimulate esophageal motility in mildly affected animals (Box 50-2).

Obstructive Lesions

Persistent right aortic arch is the most common vascular ring anomaly recognized in dogs and cats (Muldoon et al, 1997). This anomaly results in constriction of the esophagus at the level of the heart base by the right fourth aortic arch and the ligamentum arteriosum. Esophageal dilatation develops proximal to the vascular ring, leading to regurgitation. Esophageal motility defects may persist if the obstructive lesion is not surgically corrected before irreversible damage to esophageal function occurs.

Esophageal obstruction due to stricture formation may occur as a consequence of recurrent or severe esophageal injury. Strictures occur most commonly due to esophageal foreign bodies or as sequelae to gastroesophageal reflux during general anesthesia. Rarely, infectious (e.g., pythiosis), parasitic (e.g., *Spirocerca lupi*) or neoplastic conditions can result in obstructive esophageal lesions (Mylonakis et al, 2008).

Box 50-2. Swallowing Reflex.

In animals with simple stomachs, deglutition is a sequential, complex, coordinated action that transports food and liquid from the oral cavity to the stomach. It has been divided into three phases: oropharyngeal, esophageal and gastroesophageal.

The oropharyngeal phase begins with the formation of a bolus in the mouth and ends as the bolus passes through the cricopharyngeal area. Pharyngeal contraction is coordinated with relaxation of the upper esophageal sphincter. Following passage of the bolus, the upper esophageal sphincter contracts to close the upper esophagus and to initiate the esophageal phase of swallowing.

The esophageal phase of deglutition begins with the arrival of the bolus in the cranial esophagus. This phase encompasses passage of the bolus from the cranial esophagus to the gastroesophageal junction (GEJ). Four sequences of events that might occur during the esophageal phase have been described.

1. A swallow is followed immediately by an esophageal peristaltic wave, which progresses uninterrupted to the GEJ (primary peristalsis).
2. Liquid and some solid boluses remain in the proximal esophagus until a second or third swallow occurs, then a peristaltic wave carries the combined boluses to the GEJ (primary peristalsis). Other solids immediately move down the esophagus.
3. A bolus temporarily pauses in the proximal esophagus, then a stimulated peristaltic wave carries it to the GEJ (secondary peristalsis).
4. Several boluses accumulate in the proximal esophagus, then a stimulated peristaltic wave carries them to the GEJ (secondary peristalsis).

Direct stimulation of the esophageal wall by a bolus initiates a second peristaltic wave. This is also the pathway for perpetuation of the primary wave; sensory stimulation from the bolus continues as it moves down the esophagus. Progression of primary or secondary peristaltic contractions depends on the presence, size and location of the bolus in the esophagus. In the absence of a bolus, peristalsis in the esophagus does not follow the act of swallowing. In the thoracic esophagus, contractions are facilitated by, but do not depend on a bolus. Thus, two mechanisms are involved in the regulation of esophageal contraction: 1) a central regulatory mechanism (swallowing center) in the brainstem and 2) afferent nerve

impulses that originate in the esophagus in the presence of a bolus.

The lower esophageal sphincter (LES) is not a true anatomic sphincter, but rather a physiologic high-pressure zone. This zone is found in the most distal portion of the esophagus and separates the esophagus from the stomach. The LES is the functional term used for this region, but many authors use the anatomic term GEJ. During peristalsis, the LES relaxes and allows the bolus to pass into the stomach (gastroesophageal phase). A prevalent misunderstanding is that LES relaxation and opening are synonymous. Relaxation and opening of the LES are related but distinct events. LES opening is a passive mechanical event affected by the force of an oncoming bolus, whereas LES relaxation occurs as an active reflex process mediated neurologically. The average canine LES begins to relax several seconds before the esophageal pressure wave peaks in the distal esophagus. Even if the LES opens and closes normally, synchronization of LES with the esophageal wave is still required for normal passage of a bolus. It closes after passage of the bolus to prevent gastroesophageal reflux.

The GEJ is the only area of the gastrointestinal tract in which luminal structures having opposite cavitory pressures are in continuity. Mechanical factors and intrinsic LES tone serve as the major control mechanisms to prevent reflux of gastric contents. Whatever external force or positive pressure is applied to the stomach is also exerted on the terminal abdominal esophagus; therefore, no pressure gradient occurs between the stomach and thoracic esophagus. Other mechanical factors that prevent gastroesophageal reflux include: 1) interdigitating gastric rugal folds, 2) focal thickening of the distal esophageal muscle coat (in the dog there is an inner section of smooth muscle), 3) oblique implantation of the distal esophagus into the stomach and 4) the flap-like cardiac incisura, which is pushed against the GEJ by the enlarging gastric fundus. Gastrin and other gastrointestinal hormones at pharmacologic doses appear to increase LES tone. Whether these hormones function to increase LES tone when released physiologically during normal food ingestion is still speculative.

The Bibliography for **Box 50-2** can be found at www.markmorris.org.

Inflammation/Degeneration

Esophagitis arises most often as a consequence of gastroesophageal reflux or foreign body ingestion (Sellon and Willard, 2003). The GEJ serves as a barrier preventing reflux of gastric contents including pepsin and hydrochloric acid into the lumen of the esophagus. Postprandially, GEJ pressure increases in response to neural and hormonal stimuli. Certain gastrointestinal (GI) hormones, including gastrin, pancreatic polypeptide, motilin and substance P increase GEJ pressure, whereas others (i.e., secretin, cholecystokinin) reduce GEJ pressure. Dietary influences on the GEJ pressure are presumably mediated via GI hormone release. High-protein meals increase GEJ pressure through gastrin release, whereas high-fat foods reduce GEJ pressure via cholecystokinin release.

The most common cause of esophagitis in dogs and cats

appears to be anesthesia-associated reflux of gastric contents into the esophagus (Sellon and Willard, 2003). Certain sedatives, including acepromazine, xylazine and diazepam reduce GEJ pressure and may predispose an animal to reflux esophagitis following anesthetic episodes (Strombeck and Harrold, 1985; Hall et al, 1987). Recently, anesthetic-associated gastroesophageal reflux has been demonstrated to occur equally in dogs maintained under anesthesia for orthopedic procedures with isoflurane, halothane or sevoflurane (Wilson et al, 2006). Fifty-one of 90 dogs studied developed acid reflux within 30 to 90 minutes following induction and 13 of 90 patients regurgitated.

Foreign body ingestion is most commonly reported in young patients. However, certain feeding practices can result in esophageal foreign bodies in adult patients. Feeding vegetable-based dental chews and treats, bones and rawhide

Table 50-3. Key nutritional factors for foods for patients with swallowing disorders due to obstructive lesions or aberrant motility.*

Factors	Recommended levels
Energy density	≥4.5 kcal/g (≥18.8 kJ/g)
Fat	≥25%
Protein	≥25% for dog foods ≥35% for cat foods

*Nutrients expressed on a dry matter basis; food form is also a key nutritional factor but varies with individual patients (see text).

Table 50-4. Key nutritional factors for foods for dogs and cats with esophagitis/gastroesophageal reflux.*

Factors	Recommended levels
Energy density	≥4 kcal/g (≥16.7 kJ/g)
Fat	≤15% for dog foods ≤20% for cat foods
Protein	≥25% for dog foods ≥35% for cat foods

*Nutrients expressed on a dry matter basis; food form is also a key nutritional factor, but varies with the disease and individual patients (see text).

chews have resulted in esophageal foreign bodies (Rousseau et al, 2007; Leib and Sartor, 2008). In a recent retrospective review, 46 of 60 esophageal foreign bodies removed from dogs were bones (Rousseau et al, 2007). Occasionally, consumption of irritative substances such as strong acids or alkalis may cause serious esophagitis. Drug-induced esophageal disease is common in people (Sellon and Willard, 2003) and has been reported to occur in cats receiving antibiotic tablets or capsules via a “dry swallow.” In cats, esophageal transit times are prolonged following the administration of dry capsules as compared to capsules followed by a water bolus (Westfall et al, 2001). Administration of oral antibiotics to cats should be accompanied by wet food and/or a water bolus (Westfall et al, 2001; Beatty et al, 2006).

Iatrogenic esophagitis may occur as a sequela to nasoesophageal intubation when the feeding tube crosses the GEJ, resulting in incompetence of the sphincter (Lantz et al, 1983). Hiatal hernias are rarely reported in dogs and cats, but can interfere with the function of the GEJ.

Key Nutritional Factors

Key nutritional factors for patients with swallowing disorders are summarized in Tables 50-3 and 50-4 and discussed in detail below. Patients with swallowing disorders are often debilitated and growth of very young patients is often stunted. In addition to the key nutritional factors discussed here, other nutritional factors may be important depending on the lifestage and body condition of the patient.

Energy and Fat

In patients with motility and obstructive disorders, a relatively high energy density is helpful in meeting the patient’s caloric

requirement in a small volume of food relative to lower fat foods. Foods with at least 25% dry matter (DM) fat and energy densities of at least 4.5 kcal/g (18.8 kJ/g) DM are recommended. However, a lower fat content (≤15% DM for dogs and ≤20% DM for cats) is a better option for cases of esophagitis due to gastric reflux. High dietary fat delays gastric emptying and reduces lower esophageal sphincter pressure, which promotes reflux of food and gastric secretions into the esophagus (Washabau and Hall, 1997). However, these patients also need relatively energy dense foods (at least 4 kcal/g DM [16.7 kJ/g]). An energy dense, moderate fat food is recommended for patients with esophagitis/gastroesophageal reflux. Foods with these characteristics tend to be highly digestible.

Protein

Protein is required in amounts adequate for tissue repair and to support growth in young patients. Additionally, dietary protein may play an important role in reducing episodes of gastroesophageal reflux because protein stimulates an increase in gastroesophageal sphincter pressure. This effect is linked to dietary protein’s stimulatory effect on gastrin and gastric acid secretion (Guilford, 1996). By increasing the lower esophageal sphincter pressure, episodes of gastroesophageal reflux are decreased, thus limiting the potential for further esophageal injury or aspiration pneumonia. For these reasons, dietary protein content should be at least 25% DM for foods for adult dogs and at least 35% DM for foods for adult cats.

Food Form

Foods of differing consistency should be used to determine the best texture for individual patients. A liquid or gruel consistency is usually best for patients with cricopharyngeal dysphagia, esophageal obstructive lesions and/or esophagitis and may be effective in patients with megaesophagus. Esophageal performance may improve in patients with megaesophagus when the swallowing reflex is maximally stimulated by the texture of dry foods or when moist foods are formed into large boluses. Dry food or boluses of moist food may act as a stimulus (secondary peristalsis) to any remaining normal esophageal tissue. Gruels or liquids may not stimulate secondary peristalsis, thereby increasing the risk of aspiration pneumonia.

FEEDING PLAN

The goals of dietary management for patients with megaesophagus are to minimize regurgitation, avoid secondary aspiration pneumonia and to provide adequate nutrition to regain or maintain proper body weight and condition.

Assess and Select the Food

The appropriate key nutritional factor profile and the form of the food recommended for use in patients with pharyngeal/esophageal disorders depend on whether the problem is due to obstructive lesions/aberrant motility or underlying inflammatory conditions.

Table 50-5. Key nutritional factor content of selected commercial veterinary therapeutic foods for dogs with esophagitis/gastroesophageal reflux compared to recommended levels.*

Dry foods	Energy density (kcal/cup)**	Energy density (kcal/g)	Fat (%)	Protein (%)
Recommended levels	–	≥4	≤15	≥25
Hill's Prescription Diet i/d Canine	379	4.2	14.1	26.2
Iams Veterinary Formula Intestinal Low-Residue	257	3.8	10.7	24.6
Medi-Cal Gastro Formula	330	na	13.9	22.9
Purina Veterinary Diets EN GastroENTERic Formula	397	4.2	12.6	27.0
Royal Canin Veterinary Diet Intestinal HE	389	4.5	22.0	33.0
Moist foods	Energy density (kcal/can)**	Energy density (kcal/g)	Fat (%)	Protein (%)
Recommended levels	–	≥4	≤15	≥25
Hill's Prescription Diet i/d Canine	485/13 oz.	4.4	14.9	25.0
Iams Veterinary Formula Intestinal Low-Residue	413/14 oz.	4.6	13.2	35.9
Medi-Cal Gastro Formula	455/396 g	na	11.7	22.1
Purina Veterinary Diets EN GastroENTERic Formula	423/354 g	4.0	13.8	30.5
Royal Canin Veterinary Diet Intestinal HE	446/396 g	4.3	11.8	23.1

Key: na = information not available from manufacturer.

*From manufacturers' published information or calculated from manufacturers' published as-fed values; all values are on a dry matter basis unless otherwise stated.

**Energy density values are listed on an as fed basis and are useful for determining the amount to feed; cup = 8-oz. measuring cup. To convert to kJ, multiply kcal by 4.184.

Obstructive Lesions and Aberrant Motility

Feeding a high-calorie, high-fat balanced growth or recuperative food (a working/sporting food for dogs) is appropriate for most patients with megaesophagus, cricopharyngeal achalasia or obstructive lesions. The food consistency that best promotes flow through the esophagus to the stomach is determined in each case by trial and error.

Gruels often work well, which necessitates using foods with high water content (>80%). Moist foods are typically made with ingredients that blenderize easily with water. For example, meat ingredients containing connective tissue and bone do not blenderize as easily as skeletal muscle and organ protein sources. Therefore, using nutrient-dense products made from highly digestible ingredients is more likely to meet the nutrient requirements of the patient in the smallest volume possible. Recommending larger cans of calorically dense cat food can help reduce the volume and cost of feeding a large dog.

However, esophageal performance may improve in megaesophagus patients when the swallowing reflex is maximally stimulated by the texture of dry foods or moist foods formed into large boluses. These food forms may act as a stimulus (secondary peristalsis) to any remaining normal esophageal tissue whereas, gruels or liquids may not stimulate secondary peristalsis, thereby increasing the risk of aspiration pneumonia.

Comparing the key nutritional factor content of a food being considered with the recommendations in Table 50-3 will facilitate the selection process. Tables 17-4, 18-12, 24-3, 25-8 and 25-9 are also useful.

Inflammatory Conditions

Foods with lower levels of dietary fat are recommended for managing patients with esophagitis and gastroesophageal reflux. Higher dietary fat levels may precipitate gastroesophageal reflux by delaying gastric emptying and reducing lower esopha-

geal sphincter pressure. Increased dietary protein enhances lower esophageal sphincter tone. Tables 50-5 and 50-6 compare the key nutritional factor content of selected veterinary therapeutic foods to the recommended levels for canine and feline patients, respectively, with esophagitis and gastroesophageal reflux. As mentioned above, moist foods are usually more readily liquefied.

Assess and Determine the Feeding Method

Patients with swallowing disorders often require specialized feeding methods because the current feeding protocol of one to three meals per day fed in a bowl on the floor is rarely appropriate. In addition to a change to the appropriate food (including form), the key tools of nutritional management in these cases are a change in the feeding method.

Small-volume, frequent meals are recommended when feeding patients with swallowing disorders. Gruel-type foods are often necessary because the liquid form is more amenable to gravity fill of the stomach. Feeding a high-calorie food to a patient in an upright position and maintaining this position for 20 to 30 minutes after feeding provides ample time for gravitational flow of the food through the esophagus to the stomach. Upright feeding can be accomplished by several methods. The most common technique is to elevate the food bowl so that the dog or cat has to sit down or stand on its hind legs to eat. Pets can be trained to eat on stairs or from a counter or stool. Alternatively, small dogs and cats can be cradled in an upright position in the owner's arms while eating (Figure 50-5). Large dogs can be trained to sit after eating or lie in sternal recumbency on an inclined board for the required period of time. Several companies manufacture devices to facilitate upright feeding (Figure 50-6).

In some patients, upright feeding is inadequate to control regurgitation or is impractical because of the pet's temperament or

Table 50-6. Key nutritional factor content of selected commercial veterinary therapeutic foods for cats with esophagitis/gastroesophageal reflux compared to recommended levels.*

Dry foods	Energy density (kcal/cup)**	Energy density (kcal/g)	Fat (%)	Protein (%)
Recommended levels	–	≥4	≤20	≥35
Hill's Prescription Diet i/d Feline	483	4.3	20.2	40.3
Iams Veterinary Formula Intestinal Low-Residue	348	3.9	13.7	35.8
Medi-Cal Hypoallergenic/Gastro	350	na	11.5	29.8
Purina Veterinary Diets EN GastroEnteric Formula	572	4.4	18.4	56.2
Royal Canin Veterinary Diet Intestinal HE 30	396	4.4	23.7	34.4
Moist foods	Energy density (kcal/can)**	Energy density (kcal/g)	Fat (%)	Protein (%)
Recommended levels	–	≥4	≤20	≥35
Hill's Prescription Diet i/d Feline	161/5.5 oz.	4.2	24.1	37.6
Iams Veterinary Formula Intestinal Low-Residue	169/6 oz.	4.0	11.7	38.4
Medi-Cal Hypoallergenic/Gastro	184/170 g	na	35.9	35.5
Medi-Cal Sensitivity CR	162/165 g	na	35.1	34.5

Key: na = information not available from manufacturer.

*From manufacturers' published information or calculated from manufacturers' published as-fed values; all values are on a dry matter basis unless otherwise stated.

**Energy density values are listed on an as fed basis and are useful for determining the amount to feed; cup = 8-oz. measuring cup. To convert to kJ, multiply kcal by 4.184.



Figure 50-5. Upright feeding position that can be used for cats and small dogs with megaesophagus.



Figure 50-6. Feeding device that can be used to maintain an upright feeding position for patients with megaesophagus.

the owner's schedule. In those cases, placement of a gastrostomy or enterostomy tube is recommended to bypass the esophagus entirely. Nasoesophageal, nasogastric and esophagostomy tubes are not appropriate in this situation because they deliver food into the esophagus where it can be regurgitated. Patients with ongoing signs of malnutrition at presentation should receive a large-bore gastrostomy feeding tube, if possible, and immediate alimentation via the tube until adequate oral intake can be achieved. Gastrostomy tubes have been used successfully for long periods to maintain the nutritional status of dogs with megaesophagus. A permanent button-type gastrostomy tube should be considered in cases in which owners are willing to feed their pet long-term via gastrostomy tube. Even with the use of gastrostomy tubes, regurgitation of saliva and food refluxed from the stomach may still occur, which can result in aspiration pneumonia. Some clinicians prefer feeding via enterostomy tube because of the potential for gastroesophageal reflux and recurrent aspiration. Owners should be made aware that regurgitation might not completely cease even if all food and water is administered through the gastrostomy tube. Many patients will continue to regurgitate fluid, which is most likely salivary secretions. However, the likelihood of aspiration pneumonia is reduced greatly.

Pharyngeal and esophageal tissues heal slowly and are susceptible to secondary bacterial infections. Therefore, surgeons have traditionally recommended withholding oral feedings of regular pet foods for three to four days for patients with inflammation, trauma or surgery to these tissues. Patients with no history or evidence of malnutrition may be safely held off food (but not water) for two to three days if necessary, but should receive nutrition by the fourth day. Percutaneous endoscopic gastrostomy tube placement may be useful in patients after dilatation of esophageal strictures or in pets with severe esophagitis secondary to foreign body removal. The tubes can be placed at the time of an endoscopic esophageal examination. Dietary goals in

these patients are to provide adequate nutrition to the patient using foods that minimize irritation and trauma to sensitive pharyngeal and esophageal tissues.

CONCURRENT THERAPY

The feeding plan is often used in conjunction with other therapeutic modalities including surgery (e.g., cricopharyngeal myotomy, esophageal stricture, vascular ring anomaly, esophageal foreign bodies), bougienage (e.g., esophageal stricture), endoscopy (e.g., foreign body removal) and drugs (e.g., antibiotics, prokinetic agents, corticosteroids, antacids, H₂-receptor blockers, mucosal protective agents).

REASSESSMENT

Nutritional reassessment of patients with swallowing disorders includes: 1) monitoring changes in body weight and condition,

2) evaluating owner compliance regarding feeding the proper amount of food to the patient, 3) determining the extent of ongoing dysphagia or regurgitation and 4) monitoring resolution of other concurrent disease processes (e.g., pneumonia, myopathies, endocrinopathies). Daily food dosage should be adjusted as indicated by changes in the patient's body weight and condition.

ENDNOTE

a. Davenport DJ, Ware W. The Ohio State University, Columbus. Unpublished data. 1986.

REFERENCES

The references for **Chapter 50** can be found at www.markmorris.org.

CASE 50-1

Regurgitation in a Collie

Deborah J. Davenport, DVM, MS, Dipl. ACVIM (Internal Medicine)
Hill's Science and Technology Center
Topeka, Kansas, USA

Patient Assessment

A six-year-old, neutered female collie dog was examined for regurgitation and coughing of two weeks' duration. The owners had first noticed what they described as vomiting two weeks earlier. Further questioning confirmed that the problem was probably regurgitation because the process involved casting up undigested food in a tubular form with little or no force, rather than forceful expulsion of digested food with retching and involuntary abdominal contractions. Soft coughing and a mucoid nasal discharge began about a week after the onset of regurgitation. The dog was also somewhat lethargic.

Physical examination revealed a quiet, thin (body condition score [BCS] 2/5), mildly febrile (39.1°C [102.5°F]), 23-kg dog with an increased respiratory rate (45 breaths/min.). Slight mucopurulent discharge was noted in both external nares. Low-pitched, coarse crackles were heard over the entire lung field, but were loudest in the ventral half of the thorax. The coat appeared dry and lusterless. When this finding was mentioned to the owners, they confirmed that a change in coat quality had occurred more than a year ago.

Initial diagnostic evaluation included a complete blood count (neutrophilic leukocytosis), serum biochemistry profile (normal), urinalysis (normal), fecal flotation (whipworm ova) and thoracic radiography (changes consistent with megaesophagus and mild bronchopneumonia).

Further testing was done to rule out secondary or acquired causes of megaesophagus. A thorough neurologic examination failed to reveal neurologic deficits. Tests for myasthenia gravis (i.e., acetylcholine receptor antibody test) and lead toxicosis were negative. A positive-contrast esophagram revealed no evidence of strictures, granulomas, foreign bodies, neoplasia or extraesophageal compression. Results of a thyroid-screening panel included decreased serum concentrations of total thyroxine (T₄) and free T₄, and increased serum concentrations of thyrotropin (TSH).

The tentative diagnoses were hypothyroidism, megaesophagus and aspiration pneumonia.

Assess the Food and Feeding Method

The dog was normally fed a dry specialty brand food twice daily mixed with a small amount of various moist grocery brand foods. A homemade mixture of chicken and rice had also been offered during the past week in an effort to control the regurgitation.

Questions

1. What are the key nutritional factors to consider for this patient?
2. Outline an appropriate feeding plan (foods and feeding method) for this dog.

Answers and Discussion

1. Key nutritional factors for patients with megaesophagus and other motility or obstructive-type swallowing disorders include energy, fat, protein and food form. These patients are often debilitated because of inadequate food intake and secondary aspiration pneumonia. A relatively high-fat ($\geq 25\%$ dry matter [DM] fat) energy-dense (≥ 4.5 kcal/g [18.8 kJ/g] DM) food helps meet the patient's caloric requirement in small volumes. Protein is required in amounts adequate to support tissue repair and help reduce episodes of gastroesophageal reflux. Dietary protein should generally be at least 25% DM. The food form may influence esophageal motility and subsequent clinical signs. Esophageal performance in patients with congenital or acquired esophageal dilatation may improve when the swallowing reflex is maximally stimulated by the texture of coarse, dry foods. Dry food boluses may stimulate any remaining normal esophageal tissue; therefore, dry foods are the form of choice because gruels may increase the risk of aspiration pneumonia.
2. The goals of dietary management for patients with megaesophagus are to minimize regurgitation, avoid secondary aspiration pneumonia and provide adequate nutrition to regain or maintain proper body weight and condition. In this case, the feeding plan was used in conjunction with thyroid hormone replacement and treatment of the aspiration pneumonia. (See Progress Notes below.) The acquired esophageal motility defect may or may not be reversible. A high-fat, high-calorie recuperative, working/sporting dog or growth-type food is appropriate for this patient. The food should be given in small-volume, frequent meals and offered so the dog eats in an upright position. The food consistency and feeding method that best promote flow through the esophagus to the stomach in individual patients are often determined by trial and error.

Progress Notes

Thyroid hormone replacement therapy was started using 0.6 mg per day of oral synthetic levothyroxine sodium^a (L-thyroxine). The pneumonia was treated with one injection of enrofloxacin (Baytril^b) followed by oral enrofloxacin tablets (68 mg, b.i.d.) for three weeks. The whipworm infection was treated with a broad-spectrum anthelmintic (Drontal Plus^b). The food was changed to a commercial dry veterinary therapeutic food designed for stress and recovery. This food has increased fat levels (25% DM) and energy density (4.8 kcal/g [20.1 kJ] DM) and increased protein levels (38.1% DM) to support recovery and weight gain. Daily energy requirement was estimated to be 1,400 kcal (5.86 MJ) for an ideal body weight of 27 kg. The food was given in small, frequent meals and offered from a bowl placed on the edge of a table.

The coughing and nasal discharge gradually improved so the antibiotic was discontinued. Regurgitation continued but gradually lessened in frequency. Radiographs six weeks later revealed no evidence of aspiration pneumonia, but the megaesophagus was still evident. Body weight (26.5 kg) and body condition (BCS 3/5) had improved. The food was changed to the commercial dry specialty brand food originally fed to the dog but it was offered from an elevated position. This feeding plan successfully reduced the regurgitation to a few episodes per week.

Endnotes

- a. Soloxine. Daniels Pharmaceuticals Inc., St Petersburg, FL, USA.
- b. Baytril. Bayer Animal Health, Shawnee, KS, USA.

Bibliography

- Guilford WG, Strombeck DR. Diseases of swallowing. In: Guilford WG, Center SA, Strombeck DR, et al, eds. *Strombeck's Small Animal Gastroenterology*, 3rd ed. Philadelphia, PA: WB Saunders Co, 1996; 211-238.
- Jaggy A, Oliver JE. Neurologic manifestations of thyroid disease. *Veterinary Clinics of North America: Small Animal Practice* 1994; 24: 487-494.
- Peterson ME, Melian C, Nichols R. Measurement of serum total thyroxine, triiodothyronine, free thyroxine and thyrotropin concentrations for diagnosis of hypothyroidism in dogs. *Journal of the American Veterinary Medical Association* 1997; 211: 1396-1402.